

## Histopathology of the Pancreatic Cells of Alloxan Induced Wistar Rats Treated with *Psidium Guajava* Ethanolic Leaf Extract

Nosiri C.I<sup>1</sup>., Atasie O.C<sup>2</sup>., Alvan L.C.<sup>2</sup>, and Ifedigbo O<sup>2</sup>

Department of Biochemistry, Faculty of Biological and Physical Sciences, Abia State University, Nigeria

---

**Abstract:** The histopathological effect of the pancreatic cells of alloxan induced diabetic rats treated with ethanolic leaf extract (200 and 400mg/kg p.o) of *psidium guajava* was investigated. The experiment lasted for 10 days. A standard drug Glinbeclamide (5mg/kg p.o) was also used to compare the potency of the different doses of the extract. The alloxan (150mg/kg) treated showed loss in body weight, hyperglycemia and damage of the islet cells of the pancreas. The extract and the standard drug showed both antihyperglycemic with increase in body weight and tissue protective properties. These effects could be attributed to its antioxidant activity leading to increased glucose metabolism and regeneration of the islet cells.

**Keywords:** Alloxan, diabetes, Histopathology, pancreatic cells, *psidium guajava*,

---

### I. Introduction

*Psidium guajava* (Linn) from the Myrteaceae family is a large tropical evergreen shrub or small shade tree widely distributed in Mexico and Central America. It is cultivated today from the West Coast of Africa to the Pacific region, including India and China, with varieties originally introduced over the past 300 years from the United States [1]. Having a generally broad, low-calorie profile of essential nutrients, a single common guava (*P. guajava*) fruit contains about four times the amount of vitamin C as an orange [2]. Guavas contain both carotenoids and polyphenols which are the major classes of antioxidant pigments, giving them relatively high potential antioxidant value among plant foods[3]. *Psidium guajava* has been shown to possess some bioactive and chemical constituents[4] and demonstrated a lot of pharmacological activities like antispasmodic and antimicrobial properties [5]. *P. guajava* stem bark has also shown anti-hyperglycaemic effect [6] likewise the aqueous leaf extract induced with streptozotocin [7]. Many pharmacological studies have demonstrated the ability of this plant to exhibit anti-oxidant [8], cytotoxic, hepatoprotective using the aqueous leaf extract [9] anti-allergy, anticough [10], antiplasmodial, anti-inflammatory, activities supporting its traditional uses. There are so many reports on the phytochemical analyses of guava leaf which revealed the presence of more than 20 isolated compounds such as saponins, phenol, carotenoids, anthocyanins, alkaloids, tannins, vitamin C [11]. Phytochemical studies have also shown the presence of Flavanoids in particular Quercetin, Tannins, Triterpenoids, Maslinic acid, beta-sistosterol [12], Saponins, Carotenoids and Lecitin [13], Alkaloids, Glycosides and Steroids.

It has been estimated worldwide that prevalence of diabetes mellitus in 2008 was more than 347 million with varying prevalence among different ethnic groups [14] and it is expected that in 2025 the number will rise to 500 million. Diabetes mellitus is a metabolic disease with no known cure except in very specific situations. The blood glucose level becomes high due to defects in either insulin secretion where the pancreas is not producing enough insulin or insulin action in the body where the cells of the body is not responding properly to the insulin produced or both. Insulin deficiency leads to hyperglycaemia with disturbances of carbohydrate, fat and protein metabolism [15].

Alloxan-induced diabetes has been commonly demonstrated as an experimental model of insulin dependent diabetes mellitus. Alloxan action in the pancreas is preceded by its rapid uptake by pancreatic beta cells as urea analogue of glucose that has been proposed to be one of the important features to determine alloxan diabetogenicity. Damage of the cells occurs as a result of the toxic action of alloxan [16]. This has been shown with other parts of the plant with different solvents. This study was aimed at evaluating the effect of ethanol leaf extract of *psidium guajava* on blood glucose and screening the histopathological effect on the pancreatic cells in alloxan induced diabetic wistar rats.

### II. Materials And Methods

**2.1. Plant materials:** *Psidium guajava* leaves were collected from Abia State University Campus and taken to the Department of Biochemistry for air drying, and this process took 7 days to be completed. The leaves were weighed with an electric weighing balance and pulverized into a fine powder and stored ready for use.

**2.2 Animals:** Wistar albino rats (7-8weeks old) of only the male species were obtained from the animal house of the University of Nigeria Nsukka (UNN), Enugu State. The animals were fed with standard diet of vital feed Grower Mesh (Pelletised) and water was given to them in a water bottle *ad libitum* and were kept in cages. After

randomization i.e “grouping them according to their body weight” into various groups and before initiation of the experiment, the rats were acclimatized for 14 days under standard environmental conditions of temperature, relative humidity and 12 hr light and 12 hr dark cycle before the commencement of the experiment. This experiment was carried out in the animal house and laboratory of Biochemistry Department, Faculty of Biological and Physical Sciences, Abia State University, Uturu, Nigeria.

**2.3. Plant Extraction:** The powdered leaf were extracted using Soxhlet extraction unit. 500g of the dried and ground *psidium guajava* leaf was tied with a clean white muslin cloth and inserted into each of the extraction tube, 750ml of 99.9% ethanol was added into each of the conical flasks and the machine was set to boil at 60<sup>0</sup>C and later increased at random. The extract was concentrated and dried under reduced pressure in a heating and drying oven in order to evaporate the ethanol. The extract was removed from the beaker into a Bojou bottle and stored under room temperature.

**2.4. Experimental design:** Thirty (30) healthy male albino rats were used for this study weighing 120-250g. The animals had no history of having been used for an experiment or used for drug consumption. After acclimatization, the rats were divided into five groups of six each. The rats were fasted overnight prior to intraperitoneal administration of alloxan 150mg/kg b.wt. After 3 days, rats showing Random Blood Glucose (RBG) level  $\geq 140$ mg/dl (7.8mmol /L) were considered diabetic and used for the study. The ethanolic leaf extract of *psidium guajava* were administered orally daily after alloxan induction of diabetes intraperitoneally for 7 days. Treatment with the extract lasted for 10 days in which blood glucose levels were determined on day 0, 3, and 10 respectively. On days 0 and 3 glucose levels in all the groups were monitored with blood samples obtained from tail vein puncture using an automated glucose sensor machine (AccuCheck Active glucometer). On the 10th day rats were anaesthetized and peritoneal lining were excised open and careful surgical removal of the pancreas was done and preserved in formalin. Hematoxylin and Eosin staining technique was used for the histopathological effects.

The rats were randomly grouped as follows:

Group I served as control (negative control) and received normal saline

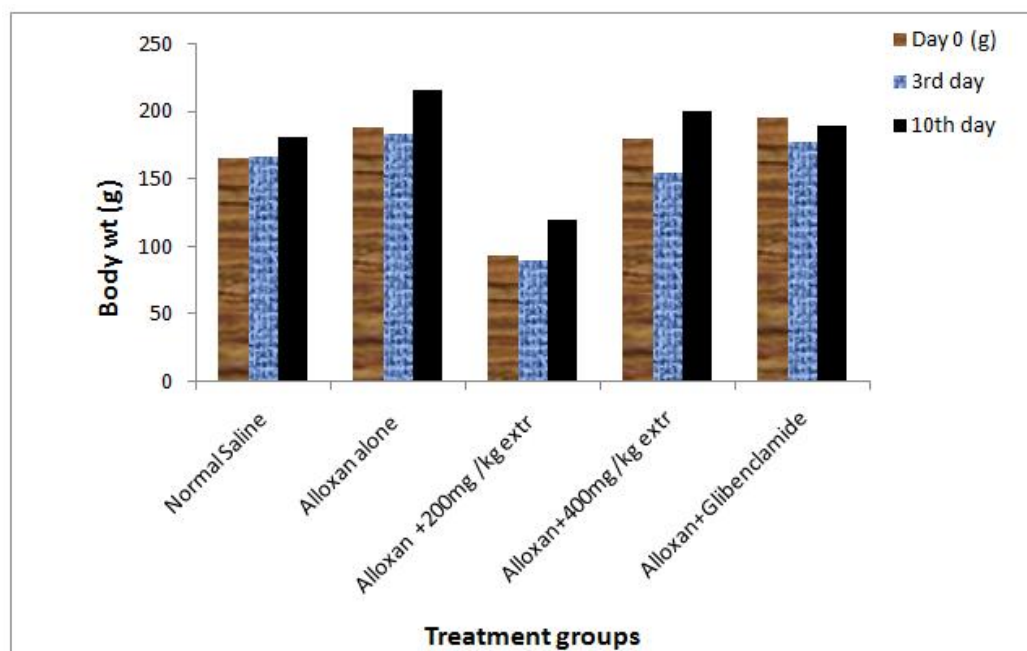
Group II served as diabetic control. (Alloxan alone 150mg/kg)

Group III Diabetic rats treated with extract (200mg/kg b.wt)

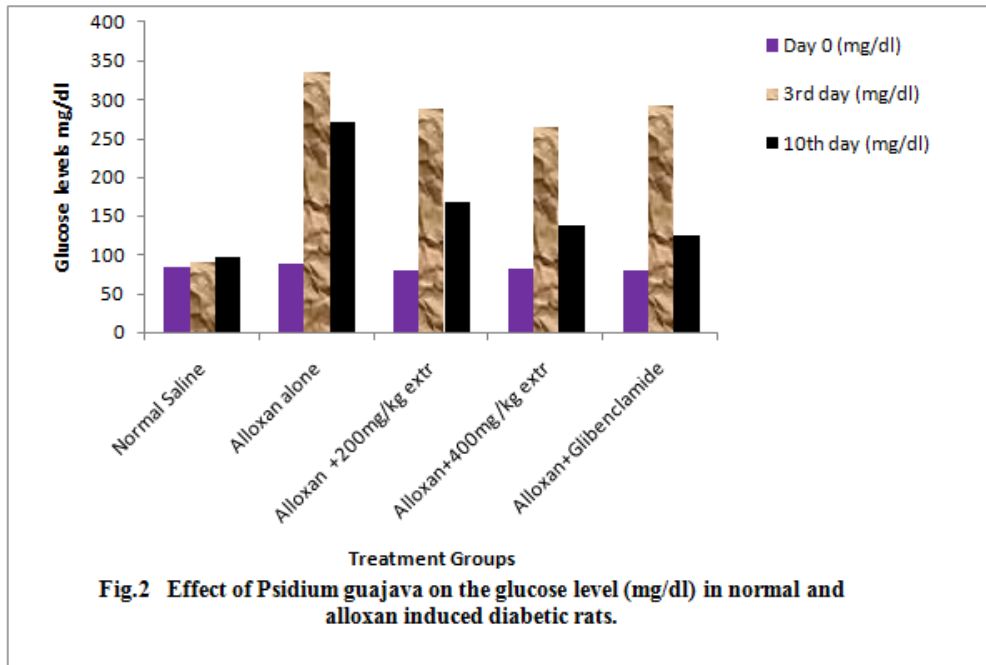
Group IV Diabetic rats treated with extract (400mg/kg b.wt)

Group V Diabetic rats treated with standard drug Glibenclamide (5mg/kg b.wt) positive control.

### III. Results



**Fig. 1** Effect of *Psidium guajava* on the body weight (g) in normal and alloxan induced diabetic rats



### 3.1.Histopathological Results

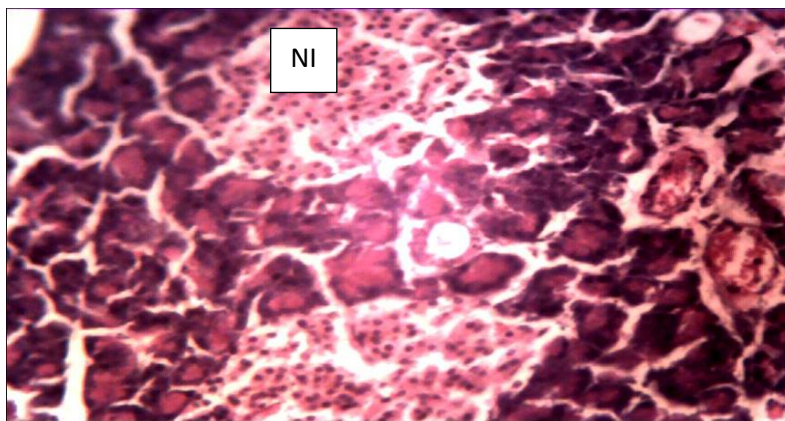


Plate I. Photomicrograph of a pancreatic section from the Normal control group showing Normal Islet (NI), H/E staining, 250x

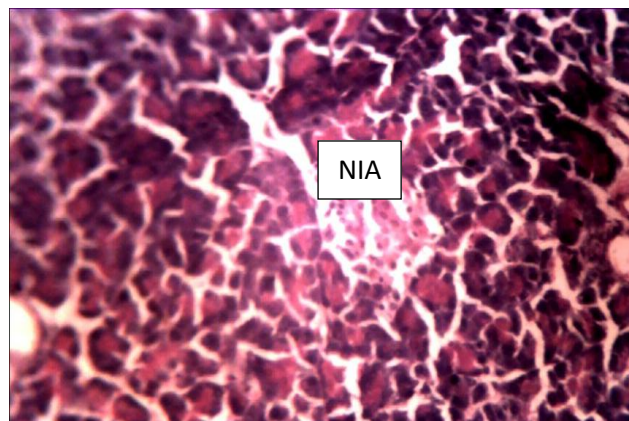


Plate II. Photomicrograph of a pancreatic section from the Alloxan treated ( diabetic control) group showing Necrosis and Islet Atrophy (NIA), H/E staining, 250x



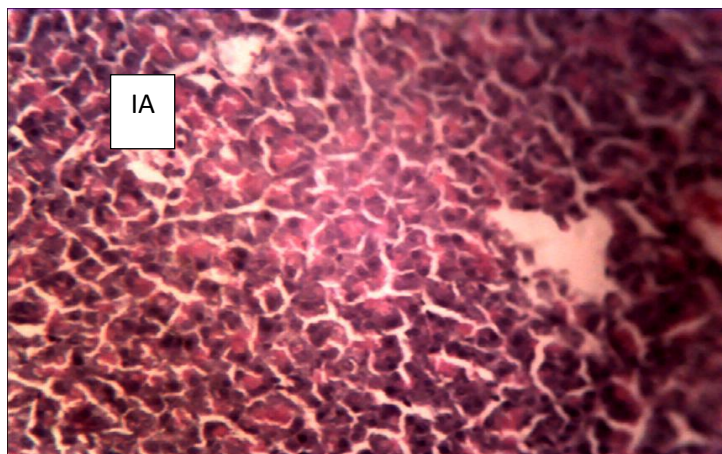


Plate III. Photomicrograph of a pancreatic section from the Alloxan treated (200mg/kg *P. guajava* leaf extract) group showing Islet Atrophy (IA), H/E staining, 250x

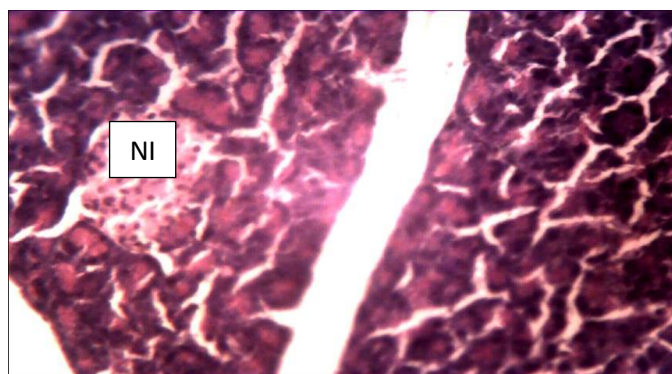


Plate IV. Photomicrograph of a pancreatic section from the Alloxan treated (400mg/kg *P. guajava* leaf extract) group showing normal islets (NI), H/E staining, 250x

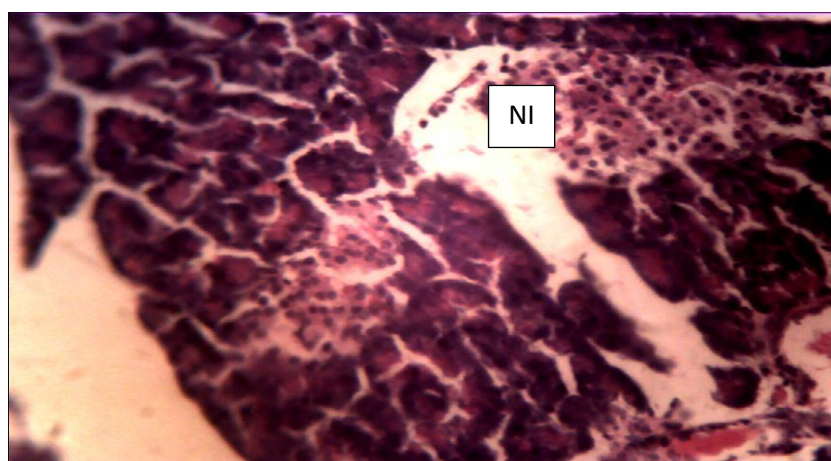


Plate V. Photomicrograph of a pancreatic section from the Alloxan treated (glibenclamide) group showing normal islets (NI), H/E staining, 250x

The results of the study indicate that ethanolic extracts of *psidium guajava* have antidiabetic (Figs 1&2) and tissue protective properties. In this study, the damage (atrophy and necrosis) of pancreatic cells in alloxan treated diabetic control rats (Plate II) and regeneration (normal Islets) of  $\beta$  cells by 400mg/kg extract (Plate IV) and glibenclamide (Plate V) respectively were observed. It was found that the ethanolic extract at high dose (400mg/kg) is more effective in reducing glucose level than at low dose (200mg/kg) after seven (7) days of treatment. Hence the above discussion revealed that ethanolic leaf extract of *psidium guajava* at high dose (400mg/kg) showed similar curative effect (Normal Islets) as standard, glibenclamide (5mg/kg).

Investigating the antidiabetic mechanism by the extract of *P.guajava* the ethanolic extracts exhibited significant anti-hyperglycemic activities in alloxan induced hyperglycemic rats with an increase in body weight, [17]. Alloxan (150mg/kg) induced weight loss in untreated rats within 10 days of the experiment whereas a gain in body weight occurred in the treated rats. The administration of *P.guajava* extracts (200 and 400mg/kg) corrected the loss in body weight and restored their levels towards normal. This could be as a result of its ability to reduce hyperglycemia by increased glucose metabolism and also due to its tissue protective effect. Alloxan is a well known diabetogenic agent that is used to induce type1 diabetes in experimental animals [18]. The underlying mechanism starts with the selective uptake of the compound due to its structural similarity to glucose as well as highly efficient uptake mechanism by Glut -2 transporter in the pancreatic beta-cells [16]. In this regard, Alloxan, an analogue of urea selectively destroys the beta-cells. This toxic action involves oxidation of essential sulphhydryl (-SH groups), inhibition of glucokinase enzyme, generation of free radicals and disturbances in intracellular calcium homeostasis [19]. *P.guajava* has been reported to possess antioxidant properties [3] which may have prevented pancreatic cell damage by the generated oxygen free radicals. Lenzen, [16] investigated the antidiabetic mechanism of Alloxan and Streptozotocin by evaluating their effects on the histology of the pancreas and livers of normal and diabetic rats and reported that the enzyme glucokinase which helps in phosphorylating glucose to G-6-P in the synthesis of glycogen for storage is being inhibited by alloxan. This inhibition reduces glucose oxidation and ATP generation thereby suppressing the signal generating metabolic flux and signal generation of ATP for glucose-induced -insulin-secretion. This could be the cause of hyperglycemia and production of lesions.

#### IV. Conclusion

The ethanol leaf extracts showed a decrease in blood sugar levels and effectively reversed the alloxan induced changes in the beta cell population of the pancreas. From the above discussion it concludes that ethanolic leaf extracts of *psidium guajava* at both high and low dose exhibited significant antihyperglycemic activity in alloxan induced diabetic rats. The action of ethanol leaf extracts on the pancreatic beta cells may offer a new hope to the diabetics in future. Further investigation is necessary to determine the exact phytoconstituents responsible for its antidiabetic effect.

#### References

- [1]. B. Joseph and M. Priya, Review on nutritional, medicinal and pharmacological Properties of guava (*psidium guajava*. linn.) *International Journal of Pharma and Bio Sciences*, 2 (1) 2011, 53
- [2]. N. M.A. Hassimotto, M.I. Genovese, F.M. Lajolo, Antioxidant activity of dietary fruits, vegetables, and commercial frozen fruit pulps. *Journal of Agri-culture and Food Chemistry* 53, 2005, 2928-2935
- [3]. A. Jimenez-Escrib, M. Rincon, R. Pulido, and F. Saura-Calixto, Guava fruit (*Psidium guajava* L.) as a new source of antioxidant dietary fiber. *J. Agri. Food Chem.*, 49, 2001, 5489-5493
- [4]. W. Fang , C. Yong-Hong ,Yu-JieZhang, D. Gui-Fang ,Z. Zhi-Fei ,An-NaLi, Dong-PingXu, Hua-Bin Li, Chemical Components and Bioactivities of *Psidium guajava*, *International Journal of Food Nutrition and Safety*, 5(2), 2014, 98-114
- [5]. H. Arima and G. Danno, Isolation of antimicrobial compounds from guava (*Psidium guajava* L.) and their structural elucidation, *Biosci. Biotechnol. Biochem.* 66(8), 2002, 1727-1730
- [6]. H.M.Mukhtar, S.H. Ansari., Z.A.Bhat., T. Naved, and P.Singh , Die Pharmazie, *International journal of Pharmaceutical Sciences*,61(8), 2006,725-727
- [7]. J. Ojewole, Hypoglycemic and hypotensive effects of *Psidium guajava* Linn. (Myrtaceae) leaf aqueous extract. *Method Find Exp.Clin.*,27, 2005, 689-695.
- [8]. C. Hui-Yin, and Y. Gow-Chin, Antioxidant activity and free radical-scavenging capacity of extracts from guava (*Psidium guajava* L.) leaves, *Food Chemistry*, 101(2), 2007, 686-694.
- [9]. C.K. Roy, J.V. Kamath and M. Asad, Hepatoprotective activity of *Psidium guajava* L leaf extract, *Indian J Exp Biol*, 44(4), 2006, 305-311
- [10]. P. Jaiarj, P. Khoohaswan, Y. Wongkrajang, P. Peungvicha, P. Suriyawong, M.L.S. Saraya, O. Ruangsomboon, Anticough and antimicrobial activities of *Psidium guajava* Linn. Leaf extract, *Journal of Ethnopharmacology*, 67(2) 1999, 203-212
- [11]. E.A Conde Garcia, V.T. Nascimento, Santiago, A.B. Santos, Inotropic effects of extracts of *Psidium guajava* L (guava) leaves on the guinea pig atrium, *Braz. J of Med. and Biol Res*, 36, 2003, 661-668.
- [12]. S. Begum, S.I.Hassan, B.S. Siddiqui, Two new triterpenoids from the fresh leaves of *Psidium guajava*. *Planta Med*, 68, 2002, 1149-1152.
- [13]. J.V Kamath, R. Nair, C.K. Ashok Kumar, S. Mohana Lakshmi, *Psidium guajava* L: A review, *International Journal of Green Pharmacy*,2 (1), 2008, 9-12.
- [14]. Y.A. Geidam , A.G.Ambali, P.A.Onyeyili , Phytochemical screening and antibacterial properties of organic solvent fractions of *Psidium guajava* aqueous leaf extracts, *International Journal of Pharmacol*, 3 (1), 2007, 68-73.
- [15]. K.I. Rother, "Diabetes treatment—bridging the divide", *The New England Journal of Medicine*356(15), 2007, 1499-501.
- [16]. S. Lenzen , The mechanisms of alloxan- and streptozotocin-induced diabetes, *Diabetologia* 51,(2), 2008, 216-226.
- [17]. G. Sumana and S.A. Suryawashi, Effect of vinca rosea extracts in treatment of alloxan diabetes in male albino rats. *Indian Journal of Experimental Biology*, 39, 2001, 748-758
- [18]. G.S. Viana, A.C. Medeiros, A.M. Lacerda, L.K. Leal, T.G. Vale, F.J. Matos, Hypoglycemic and anti-lipemic effects of the aqueous extract from *Cissus sicyoides*, *BMC Pharmacol*, 8, 2004, 4-9.
- [19]. T. Szkudelski, The mechanism of alloxan and streptozotocin action B cells of the rat pancreas, *Physiology, Res* 50, 2001, 536-546.