

Anatomy of Ovary of Pati and Chara-Chemballi Ducks (*Anas Platyrhynchos Domesticus*) During Laying Periods

Anil Deka^{1*}, Kabita Sarma², S.Sarma³, J.Goswami⁴ and J.D.Mahanta⁵

1. &2. Department of Anatomy and Histology, 3. Department of Veterinary Biochemistry, 4. Department of veterinary Physiology and 5. Department of Poultry Sciences, College of Veterinary Sciences, Assam Agricultural University, Guwahati-781022, Assam, India.

Abstract: The present investigation was undertaken to establish anatomical norms on gross anatomical, histological and histochemical parameter of ovary of Pati and Chara-Chemballi ducks. In present investigation, twelve each Pati and Chara-Chemballi ducks in their laying periods at 42 weeks of age were utilized. After collection of sample, it was processed as per slandered method. The mean value of length, breadth, thickness and weight of ovary of Chara-Chemballi ducks was significantly higher than Pati ducks. Histologically, the ovary was covered by simple squamous epithelium with patches of cuboidal epithelium in both the ducks. The outer cortical and inner medulla divisions of the ovary were obscured. PAS positive reaction were intense at the basement membrane of granulosa cells, strong in stratum granulosum and theca interna, and moderate in ovarian stroma, tunica albugenia and the cytoplasm of the oocytes in Chara-Chemballi duck as compared to Pati duck. Result obtained showed that the Chara-Chemballi duck revealed significant difference in gross and histochemical parameters as compared to Pati ducks but histologically, there are no significant differences of ovaries both the varieties.

Keywords: Anatomy, Ovary, Pati, Chara-Chemballi, Duck, Laying ,Periods.

I. Introduction

Ducks are one of the excellent converters of low quality waste products into high quality animal protein in the form of egg and meat. Duck eggs have great demand in the states of Assam as it has high biological value and considered to be a delicacy food item. The popularity of duck is increasing in many areas of the world as ducks are one of the most versatile and useful of all domesticated animals and birds. Duck production is found to be more profitable in Indian condition than chicken production in terms of return of cost. Assam is known to possess a good number of popular varieties of ducks. The Pati duck population constitutes a major indigenous non-descript duck variety in the state of Assam. However, Chara-Chemballi duck is the combination of Chara and Chemballi but their production performance did not differ significantly under free range condition of Assam. Ovary plays an important role in production of ovum. Although research works have been conducted on the ovary in domestic fowl [1], literature on the ovary of Pati and Chara-Chemballi ducks during laying is found to be scarce. Hence, considering the importance of these ducks the present work was undertaken to elucidate the anatomical feature of the ovary.

II. Materials And Methods

2.1: Ethical approval: The prior approval from the Institutional Animal ethical Committee was obtained for use of the animals in this study. Approval No. was 770/ac/CPCSEA/FVSc/AAU/IAEC/12-13/130.

2.2: Experimental design: In the present investigation, twelve each Pati and Chara-Chemballi ducks in their laying period at 42 weeks of age were utilized. The ovaries were collected immediately after sacrificed and the location and relative topographic in-situ position of the ovary were recorded. The ovaries were taken out from the body of birds and weights of ovaries were recorded with the help of electrical pan balances. The gross anatomical characters of ovary were studied and the different biometrical measurements viz, the length, breadth and thickness of ovaries were recorded by verniercallipers. For histological and histochemical study the tissue samples were fixed in 10% neutral buffered formalin. Paraffin blocks were cut in five micron thickness and stained with Haematoxylin and Eosin method for histomorphological observation, Van Gieson's method for collagen fibre, Gomori's method for reticular fibre, Hart's method for elastic fibre, Bielschowsky's method for nerve fibers and Mc.Manus method for glycogen [2]. The data were analyzed as per method of [3] and were presented accordingly.

III. Results And Discussion

Grossly, the mature ovary of Pati and Chara-Chemballi ducks resembled a bunch of grapes (Fig.1 and Fig.2) and was located ventral to the ventral surface of the cranial lobe of left kidney. Similar finding was

reported in fowl [4]. The ovary was attached to the cranial lobe of left kidney by dorsal ligament. It was located at the midline of the abdominal cavity. Similar findings were reported in domestic duck [5], in fowl [6, 7]. The ovary of Pati and Chara-Chemballi consisted of numerous follicles of different sizes. It was attached to the dorsal wall of the abdomen by the mesovarium. The mean biometrical value of length, breadth, thickness and weight of the left ovary was found to be significantly higher in Chara-Chemballi duck (9.83 ± 0.37 cm, 8.66 ± 0.28 cm, and 3.91 ± 0.18 cm and 88.22 ± 0.52 gm) than Pati duck (3.51 ± 0.10 cm, 2.67 ± 0.12 cm, 1.42 ± 0.08 cm and 13.90 ± 0.25 gm) (Table-1). Contrary to the present finding [1] reported that the length, breadth, thickness and weight of ovary was 3.0045 ± 0.0245 cm, 1.2460 ± 0.0286 cm, 0.3080 ± 0.0125 cm and 3.6500 ± 0.0915 gm, respectively in adult indigenous chicken of Assam where as the weight of ovary was 60 gm of domestic fowl [6], 38 gm in laying hen [8] while [9] reported that the weight of the ovary of the actively laying turkey ranged from 129 to 145 gm. These might be due to variation in size of birds. Histological, the ovary of both Pati and Chara-Chemballi ducks revealed that the ovary consisted of outer cortex and inner medulla and the division between cortical and medullary layers became obscured. Similar findings were reported in duck [10] and [11] in Japanese quail. In current study, the surface epithelium of the ovary consisted of simple squamous epithelium with patches of cuboidal epithelium. The tunica albuginea was beneath the surface epithelial layer and was formed by connective tissue fibers.

The ovarian cortex was occupied by numerous follicles of different stages of development viz., primary, secondary, tertiary and few were atretic (Fig.3& Fig.4). These were in consonance with the finding of [12] on duck and [8] in fowl. The collagens, elastic and reticular as well as nerve fibers were more in the connective tissue of Chara-Chemballi ducks than Pati ducks (Fig.7&Fig.8). However, these could not be compared due to non-availability of literature. The theca interna of the follicular wall contained more collagen fibers and few reticular, elastic and nerve fibers in Chara-chemballi duck than Pati duck. Numerous flattened fibroblasts lied among the connective tissue and smooth muscle fibers were observed at the theca externa in both Pati and Chara-Chemballi ducks (Fig.5). Similar findings were reported in Japanese quail [11].

The ovarian medulla of both Pati and Chara-Chemballi ducks consisted of numerous bloods and lymph vessels. The collagen and reticular fibers were more and less number of elastic fibers as well as nerve fibers were found in Chara-Chemballi ducks (Fig.9&Fig.10). However, in Pati ducks these connective tissue fibers were less compared to Chara-Chemballi ducks. The present study was corroborated with [13]. Histochemically, PAS reaction was intense at the perivitelline membrane (Fig.6), strong in stratum granulosum and theca interna and moderate in ovarian stroma, tunica albugenia and the cytoplasm of the oocytes in Chara-Chemballi duck as compared to Pati duck. Similar findings were recorded on duck [10]. This might be due to more amount of glycogen in perivitelline membrane and more amount collagen fibers in theca layers of the ovary of Chara-Chemballi duck as compared to Pati duck.

IV. Conclusion

Grossly, the mature ovary of Pati and Chara-Chemballi ducks resembled a bunch of grapes and it was located ventral to the ventral surface of the cranial lobe of left kidney in abdominal cavity. The ovary consisted of numerous follicles of different sizes. Histologically, the ovary was covered by simple squamous epithelium with patches of cuboidal epithelium in both Pati and Chara-Chemballi ducks. The outer cortex and inner medulla division was became obscured. Histochemically, PAS reaction was intense at the perivitelline membrane in Chara-Chemballi ducks as compared to Pati ducks.

References

- [1]. Bharati, K.S., Studies On The Gross And Histology Of Female Reproductive System Of Adult Indigenous Chicken (*Gallus Domesticus*) Of Assam, M.V.Sc. Thesis, C.V.Sc AAU, Khanapara, Guwahati-780122, 2005.
- [2]. Luna, L.G., Manuals Of Histological Staining Methods Of Armed Forces Institute Of Pathology, 3rd Edn. Mc Graw Hill Book Co., London, 1968.
- [3]. Snedecor, G.W. And Cochran, W.G., Statistical Methods. 8th Edn. Iowa State Univ. Press, Ames, Iowa, 1994.
- [4]. Dyce, K. M., Sack, W.O. And Wansing, C.J.G., Textbook Of Veterinary Anatomy. 3rd Edn. P.831-832. Saunders, Missouri, USA, 1987.
- [5]. Das, L.N., Mishra, D.B. And Biswal, G., Comparative Anatomy Of The Domestic Duck (*Anas Boscas*). Indian Veterinary Journal, 42, 1965, 320-326.
- [6]. Kings, A.S. And McLelland, J., Outline Of Avian Anatomy. Baillier Tindall, London, 1975, 67-69.
- [7]. Kings, A.S., Aves Urogenital System. In : Sisson And Grossman's The Anatomy Of The Domestic Animals. Robert Getty (Eds.), 5th Edn. Vol.2, W.B.Saunders Co., Philadelphia, 1977, P.1937.
- [8]. Nickel, R., Schummer, A. And Seiferle, E., Anatomy Of The Domestic Birds. Verlag Paul Parey, Berlin, Hamburg, 1977, 75-77.
- [9]. Dalrymple, J. R., Macpherson, J. W. And Friars, G.W., The Reproductive Tract Of The Turkey Hen (A Biometrical Study). Can.J.Comp.Med., 32, 1968, 435.
- [10]. Rao, C.T.S. And Vijayaragavan, C., Microanatomical Studies On The Ovary Of The Domestic Duck (*Anas Boschas Domesticus*). Indian Journal Of Veterinary Anatomy, 11 (2), 1999, 128-132.
- [11]. Parida, S., Sivakumar, M., Rameh, G. And Vijayaragavan, C., Histological And Histochemical Study Of Ovary In Japanese Quail (*Coturnix Coturnix Japonica*). Indian Journal Of Veterinary Anatomy, 12(1), 2000, 69-75.

- [12]. Das, L. N. And Biswal, G., Microanatomy Of The Reproductive Tract Of The Domestic Duck (Anas Boscas) Indian Veterinary Journal, 45, 1968, 1003-1009.
- [13]. Dellmann, H.D. And Carithers, J. R..., Cytology And Microscopic Anatomy.5th Edn., Lea And Febiger, Box3024, USA,1996.,275-277.

Table.1: Genetic Group Wise Average Length, Breadth, Thickness and Weight of Ovary of Pati and Chara- Chemballi Ducks Along With The Results of't' test

Traits	Genetic groups		't' Value
	Pati duck	Chara-Chemballi	
Length(cm)	3.51±0.10	9.83±0.37	16.309**
Breadth(cm)	2.67±0.12	8.66±0.28	19.286**
Thickness(cm)	1.42±0.08	3.91±0.18	12.131**
Weight(gm)	13.90±0.25	88.22±0.52	128.101**

** Highly significant (P<0.01)

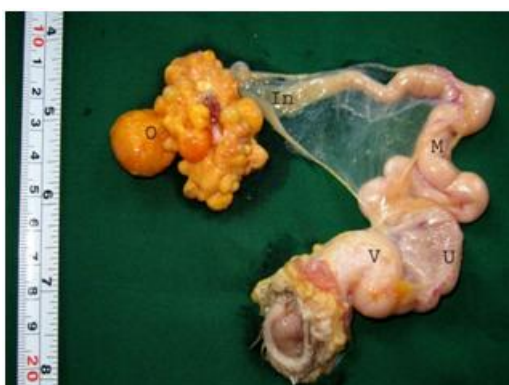

Fig.1: Photograph showing the ex-situ position of female reproductive system of Pati duck showing ovary (O), infundibulum (In), magnum (M), uterus (U) and vagina (V).

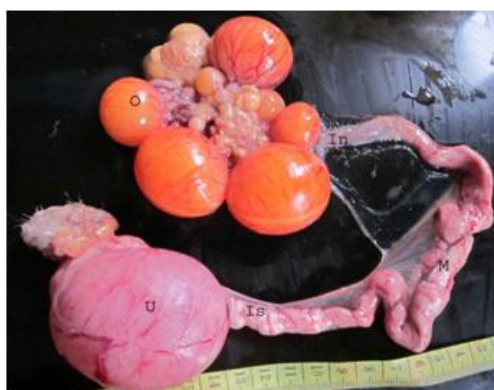

Fig.2: Photograph showing the ex-situ position of female reproductive system of Chara-Chemballi duck showing ovary (O), infundibulum (In), magnum (M), isthmus (Is) and uterus (U).

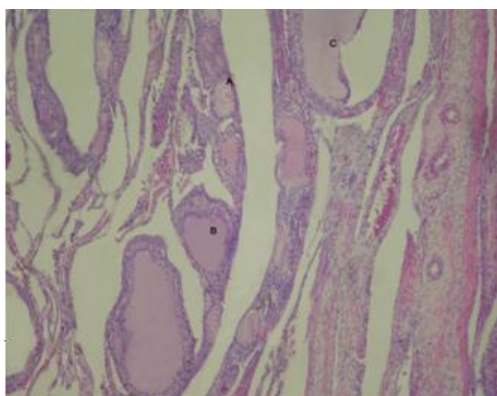


Fig.3: Photomicrograph showing the ovary of Pati duck along with primary (A), secondary (B) and tertiary follicle (C). H&E, 100X

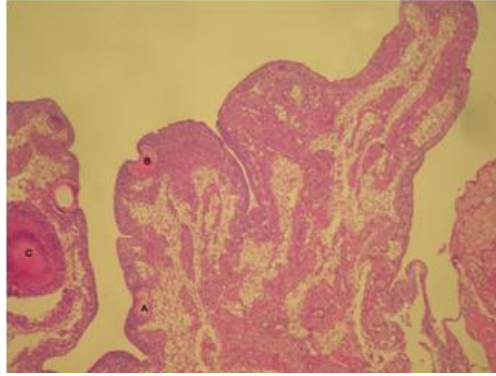


Fig.4:Photomicrograph showing the ovary of Chara-Chemballi duck along with primary (A), secondary (B) and tertiary follicle (C). H& E, 100X

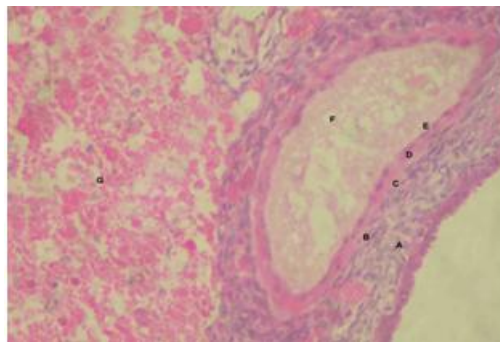


Fig.5:Photomicrograph showing the tertiary follicle, A (theca externa), B (theca interna), C (basement membrane), D (membrana granulosa), E (perivitelline membrane), F(oocyte),G (cortex) of Chara – Chemballi duck, H&E, 400X

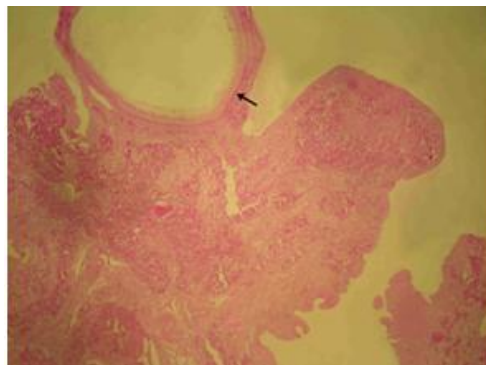


Fig.6:Photomicrograph showing the intense pas reaction in the perivitelline membrane (arrow) of ovary of Chara-Chemballi ducks. Mc Manus method for glycogen (PAS), 400X

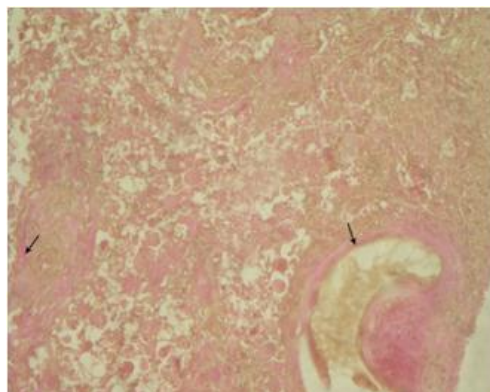


Fig.7:Photomicrograph showing the collagen fibers (arrow) of ovary of Chara-Chemballi duck. Van Gieson's, 400X

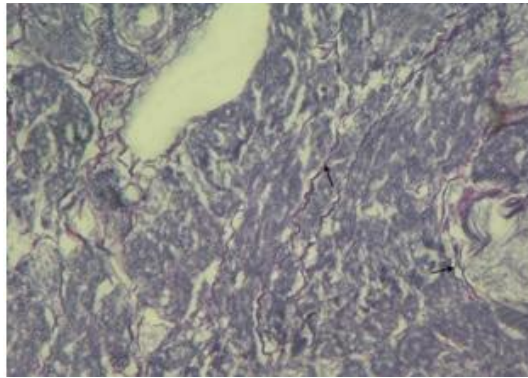


Fig.8:Photomicrograph showing the nerve fibers (arrow) of ovary of Chara-Chemballi duck. Bielschowsky's Method, 400X

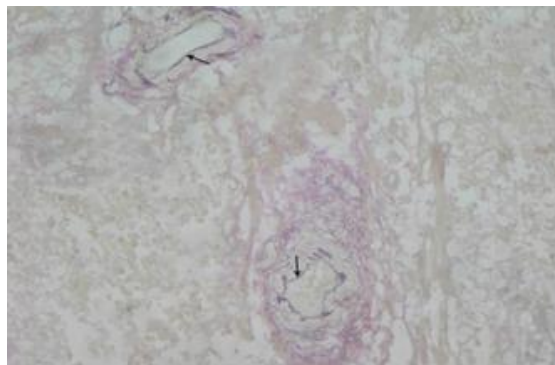


Fig.9:Photomicrograph showing the elastic fibers (arrow) of ovary of Chara-Chemballi duck. Hart's Method, 400X

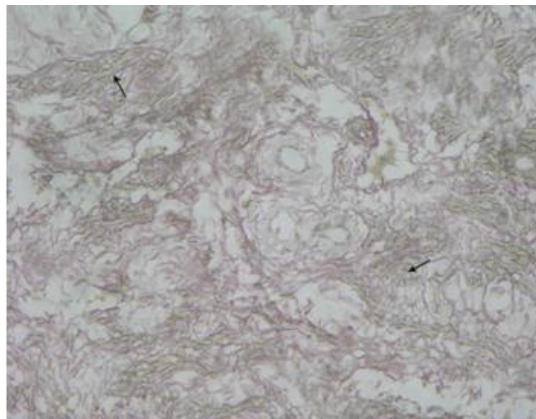


Fig.10: Photomicrograph showing the reticular fibers (arrow) of ovary of Chara-Chemballi duck. Gomori's Method, 400X