

## Caecal Development in Kuttanad Duck (*Anas Platyrhynchos Domesticus*)

A. D. Firdous<sup>1</sup>, K. M. Lucy<sup>2</sup>

<sup>1,2</sup>Department of Veterinary Anatomy and Histology, College of Veterinary and Animal Sciences, Mannuthy-680 651, Kerala, India.

---

**Abstract:** Caecum, the largest part of duck's intestine has an important role in liquid absorption, cellulose digestion and defensive mechanism. Age related changes in the histomorphology of the caeca in Kuttanad ducks were studied in 72 birds from day-old to adult at fortnight intervals. After recording the biometry and gross features, the material was fixed in neutral buffered formalin and standard procedures were adopted for histological and histochemical studies. The paired caeca extended cranially from the ileo-colic junction. Each caecum showed three regions, viz., the base, middle part and an apex. The apical portion was caudally directed and free. In day-old birds, the caecum had a uniform diameter. The adult length was attained by eight weeks of age. Histologically, ileo-caecal-colic junction showed a papilla-like protrusion made up of circular smooth muscle layer. Large nerve bundles were found in the inner circular layer of tunica muscularis in this region. Mucosa of the caecum carried tooth shaped villi, which were more prominent and longer in the basal part. Their height reduced towards the middle portion and again increased in the apex in the non-distended caecum. In day-old birds, histological picture was same as in the adult except in that there was no lymphatic tissue in the lamina propria. Lamina epithelialis was formed of simple columnar epithelium with goblet cells, the number of which decreased towards apex. Lymphatic tissue decreased towards the apex. Lamina propria was separated from the submucosa by a thin muscularis mucos. At the basal region, tunica muscularis was extremely thick forming the caecal sphincter.

**Key words:** caeca, Kuttanad, postnatal

---

### I. Introduction

The hindgut in duck is comparable to that of other birds although there are many unique aspects to consider. Caecum, the largest part of duck's intestine, has an important role in liquid absorption, cellulose digestion and defensive mechanism. Literature on postnatal development of caeca in duck is scanty. Hence this work was undertaken to study the age related changes in the caecum of Kuttanad ducks. This will form a basis for correlating the possible functions of the caeca particularly to that of defensive action in different age groups.

### II. Materials and Methods

This study was conducted on apparently healthy 72 Kuttanad ducks of various age groups. The birds were selected randomly from a single hatch and reared under semi-intensive system of management. After recording the body weight of birds, caeca were collected at two weeks interval ranging from day-old to adult. Body cavity was opened and topography of the caecum was noted. The caeca were then dissected out and examined for gross appearance, colour and shape. After recording the biometry and topography, the material was fixed in neutral buffered formalin and standard procedures were adopted for histological and histochemical studies. The sections were stained using Ehrlich's haematoxylin and eosin method, Van Gieson's method for collagen and Gomori's one step trichrome method (Luna, 1968). Measurements were taken using ocular micrometer. The data on these physical parameters were analysed statistically (Snedecor and Cochran, 1985).

### III. Results

#### a. Morphology

The paired caeca extended cranially from the ileo-colic junction. Each caecum showed three regions, viz., the base, middle part and an apex. Caecum lay parallel to the ileum and was connected to it by means of short ileo-caecal ligaments (Fig. 1). Gross and histological features of the caecum showed marked variation with the advancement of age. Measurements of caecum at various stages of development are given in table 1. Length of the caecum increased from  $4.00 \pm 0.42$  cm to  $13.69 \pm 2.45$  cm from day-old to adult. Caecum attained its adult length by eight weeks of age. Mean length showed an increasing trend upto 18 weeks of age and gradually its length decreased. Diameter of all the three regions of the day-old caecum was uniform, i.e., 0.10 cm. But in fully developed caecum, the apex showed maximum diameter. Diameters of fully developed caecum at basal, middle

and apical regions were 0.28cm, 0.38cm and 0.57cm, respectively suggesting that lumen has expanded especially in the free apical portion.

#### **b. Histology**

Histologically, ileo-caeco-colic junction showed a papilla-like protrusion made up of circular smooth muscle layer (Fig. 2). Large nerve bundles were found in the inner circular layer of tunica muscularis in this region (Fig. 3). The mucosa of the caecum carried tooth-shaped villi, which were more prominent and longer in the basal part (Fig. 4). Micrometric parameters of caecal villi revealed that the mean height of the villi increased from  $206.67 \pm 13.33 \mu\text{m}$  in day-old to  $886.67 \pm 24.7 \mu\text{m}$  in the adult at the base,  $61.33 \pm 1.33 \mu\text{m}$  to  $308.0 \pm 35.23 \mu\text{m}$  in the middle portion and  $70.0 \pm 5.77 \mu\text{m}$  to  $366.37 \pm 29.06 \mu\text{m}$  at the apex. Their height reduced towards the middle portion and again increased in the apex in the non-distended caecum.

In the day-old birds, histological picture was the same as in the adult except in that there was no lymphatic tissue in the lamina propria. Longitudinal mucosal folds were noticed in the middle and apical region as the age advanced (Fig. 5). Lamina epithelialis was formed of simple columnar epithelium with goblet cells, the number of which decreased towards the apex (Fig. 6). Lamina propria showed tubular intestinal crypts of Lieberkuhn and diffused lymphatic tissue (Fig.7). A typical caecal tonsil could not be located unlike in domestic fowl. Lymphatic tissue decreased towards the apex. Lamina propria was separated from the submucosa by a thin muscularis mucosa. Tunica muscularis showed a very thick inner circular and a thin outer longitudinal smooth muscle layers. At the basal region, tunica muscularis was extremely thick forming the caecal sphincter. Tunica muscularis showed bundles of nerve fibres. Thickness of muscular coat decreased towards the apex. Externally there was a serosa.

### **IV. Discussion**

Histomorphological age related changes were studied in duck caecum from day-old to adult. Changes in caecal length, diameter, presence of villi and lymphatic tissue were studied.

The paired caeca extended cranially from the ileo-colic junction and lay parallel to the ileum and was connected to it by means of short ileo-caecal ligaments as reported by McLelland (1975) in domestic fowl. Length showed marked increase with the advancement of age. Nickel *et al.* (1977) reported that the length of caeca in domestic duck ranged from 10 to 20 cm. In the present study, the length of caecum in the case of adult was found to be in the same range. Diameter in day-old birds was uniform but in fully developed caecum, apex attained maximum diameter.

The mucosa of the caecum carried tooth-shaped villi, which were more prominent and longer in the basal part. According to Hodges (1974) villi in duck caeca were tooth shaped and shorter than in the small intestine. In the non-distended caecum height of villi reduced towards the middle portion and again increased in the apex.

In the day-old birds, histological picture was the same as in the adult except in that there was no lymphatic tissue in the lamina propria. This may be due the minimum exposure to antigen at this age. Longitudinal mucosal folds were noticed in the middle and apical region as the age advanced. Hodges (1974) reported the presence of longitudinal mucosal folds in the caecum of fowl. Lamina epithelialis was formed of simple columnar epithelium with goblet cells, the number of which decreased towards the apex. Lamina propria showed tubular intestinal crypts of Lieberkuhn and diffused lymphatic tissue.

Lamina propria was separated from the submucosa by a thin muscularis mucosa. According to Hodges (1974), in case of domestic fowl, muscularis mucosae were very poorly developed and consisted of only a few bundles of circular muscle fibres. In the case of domestic fowl such bundles of circular muscle fibres were found to be absent in many places in the apical region of caecum as proved by Looper and Looper (1929). Tunica muscularis showed a very thick inner circular and a thin outer longitudinal smooth muscle layers. At the basal region, tunica muscularis was extremely thick forming the caecal sphincter as reported by McLelland (1975) in domestic fowl. Tunica muscularis showed bundles of nerve fibres. Mahdi and McLelland (1998) observed that the majority of nerve bundles were found in the circular muscle layer and consisted of axons with small granular vesicles, axons with small agranular vesicles and axons with many large granular vesicles.

In the case of fowl, Looper and Looper (1929) proved that in the distal 2/3<sup>rd</sup> of the caeca showed abundant lymphoid tissue. In contradiction, Das and Biswall (1967) described that lymphocytic aggregation and lymphocytic follicles with germinal centers were absent in duck. In the present study however, characteristic finding was the presence of diffused lymphatic tissue in lamina propria in growing and adult birds unlike in the case of day-old. A typical caecal tonsil could not be located unlike in domestic fowl (Hodges, 1974).

The occurrence of diffused lymphatic tissue in the lamina propria throughout the caecal wall in growing and adult birds highlights the immunological surveillance against the caecal luminal contents and thus helps in maintaining the caecal microenvironment.

**V. Conclusion**

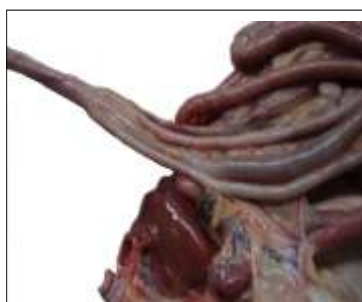Caecum attained its adult length by eight weeks of age. Mean length showed an increasing trend upto 18 weeks of age and gradually its length decreased. Diameter of all the three regions of the day-old caecum was uniform. In fully developed caecum, the apex showed maximum diameter. The mucosa of the caecum carried tooth-shaped villi, which were more prominent and longer in the basal part. Their height reduced towards the middle portion and again increased in the apex in the non-distended caecum. Longitudinal mucosal folds were noticed in the middle and apical region as the age advanced. In the day-old birds, histological picture was the same as in the adult except in that there was no lymphatic tissue in the lamina propria. Lymphatic tissue decreased towards the apex. A typical caecal tonsil could not be located unlike in domestic fowl. At the basal region, tunica muscularis was extremely thick forming the caecal sphincter. Tunica muscularis showed bundles of nerve fibres.

**References**

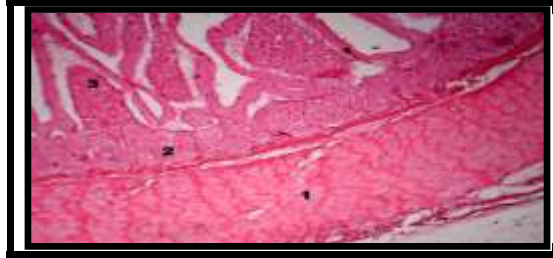
[1] DAS, L.N. and BISWAL, G. (1967) Microanatomy of intestine, pancreas and liver of the domestic duck (*Anas boscas*). *Indian Veterinary Journal* 44: 763-766. HODGES, R. D. (1974) *The Histology of the Fowl*. Academic Press, New York. 648p.  
 [2] LOOPER, J. B. and LOOPER, M.H. (1929) A histological study of the colic caeca in the bantam fowl. *Journal of Morphology* 48: 587-589.  
 [3] LUNA, L. G. (1968) *Manual of Histological Staining Methods of the Armed Forces Institute of Pathology*. Third edition, Mc Graw-Hill Book Company, New York. 258p.  
 [4] MAHDI, A. H. and MC LELLAND, J. (1988) The arrangement of the muscle at the ileo-caeco-rectal junction of the domestic duck (*Anas platyrhynchos*) and the presence of anatomical sphincters. *Journal of Anatomy* 161: 133-142.  
 [5] MC LELLAND, J. (1975) Digestive system. In: Sisson and Grossman's *The Anatomy of the Domestic Animals*. Ed. Getty, R. W. B. Saunders Co., Philadelphia. pp. 1857-1882.  
 [6] NICKEL, R., SCHUMMER, A and SEIFERLE, E. (1977) *Anatomy of the Domestic Birds*. Verlag Paul Parey, Berlin, 212p.  
 [7] SNEDECOR, G. W. AND COCHRAN, W. G. (1985) *Statistical Methods*. Seventh edition, The Iowa State University Press, USA. 313p.

**Table 1. Gross Parameters of the Caecum In Kuttanad Ducks**

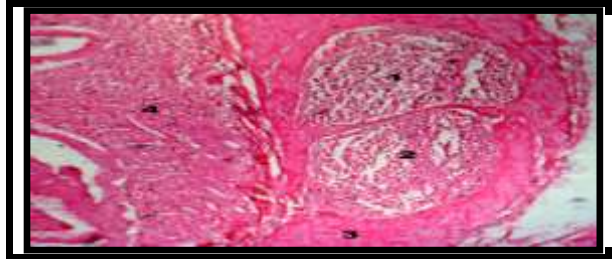
Age	Mean length of caecum (cm)	Mean diameter of caecum (cm)		
		Base	Middle	Apex
Day-old	4.00±0.42	0.10±0.00	0.10±0.00	0.10±0.00
2 wk	10.75±0.10	0.22±0.02	0.28±0.00	0.22±0.02
4 wk	13.30±0.25	0.25±0.01	0.27±0.02	0.29±0.02
6 wk	13.43±0.60	0.28±0.09	0.38±0.02	0.37±0.04
8 wk	13.60±0.94	0.34±0.03	0.38±0.00	0.40±0.04
10 wk	14.40±0.70	0.30±0.00	0.42±0.04	0.37±0.06
12 wk	15.40±0.94	0.30±0.00	0.36±0.00	0.39±0.05
14 wk	15.16±1.90	0.25±0.02	0.35±0.02	0.42±0.03
16 wk	14.30±1.48	0.27±0.00	0.29±0.00	0.34±0.02
18 wk	18.66±0.60	0.26±0.01	0.28±0.02	0.37±0.05
20 wk	16.16±1.42	0.25±0.02	0.26±0.01	0.34±0.03
22 wk	13.69±2.45	0.28±0.00	0.38±0.02	0.57±0.05



**Fig.1** Caecum attached to ileum by ileo-caecal ligaments



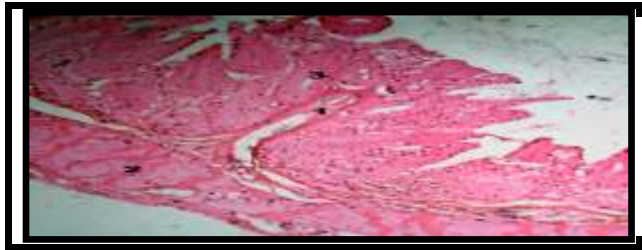
**Fig.2** 1-circular smooth muscles 2-Lamina propria 3- Villus



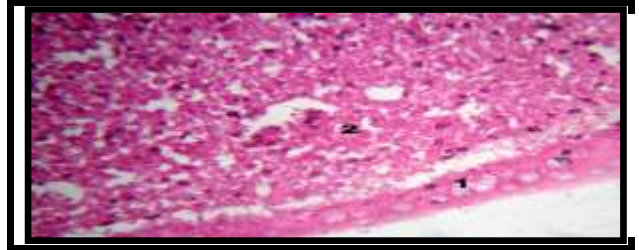
**Fig.3** 1, 2- Nerve bundles 3- Tunica muscularis 4- Lamina propria



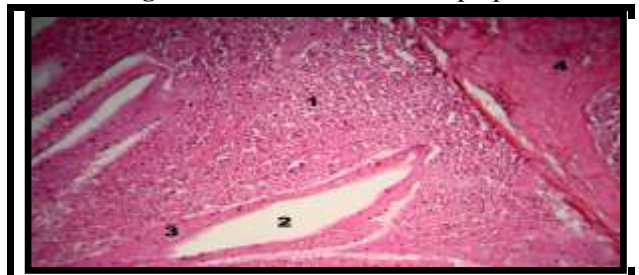
**Fig.4** 1- Tooth-shaped villi 2- Lamina propria 3- Tunica muscularis 4- Serosa



**Fig.5** 1.Longitudinal mucosal fold 2- Tunica muscularis 3- villus



**Fig.6** 1.Goblet cell 2- Lamina propria



**Fig.7** 1-Lymphatic tissue 2- Inter-villus space 3-simple columnar epithelium 4- Tunica muscularis