

## **The prevention of postoperative intra-abdominal adhesion formation with different methods: a review article**

Enis Karabulut, Ibrahim Canpolat

*Department of Surgery, Veterinary Faculty, Firat University, Elazig, Turkey*

---

**Abstract:** *Intra-abdominal adhesions are almost inevitable after major abdominal surgery. Postoperative adhesions continue to be the major cause of small bowel obstruction and infertility. Peritoneal lesions caused by abrasion, ischemia, desiccation, infection, thermal injury and foreign bodies are the origin of adhesions. Fibrinous adhesions that develop within a few hours of operational trauma. This fibrin can either re-absorb completely, leaving a clear peritoneal cavity, or become organized by the ingrowth of fibroblasts to form established fibrous adhesions. Adhesions may be diminished in five ways: First, the initial injury can be minimized. Second, the coagulation of exudate can be prevented. Third, prolonged contact of surfaces can be reduced. Fourth, fibrin can be removed after it is formed, and fifth, fibroblast proliferation can be stopped or slowed. Laparoscopic adhesiolysis would be more effective in preventing reformation of adhesions than adhesiolysis with laparotomy. This review include events leading to the formation of adhesions, pathogenesis of adhesions and attempts to prevent adhesions.*

**Keywords:** *Adhesion, intra-abdominal, postoperative, prevention.*

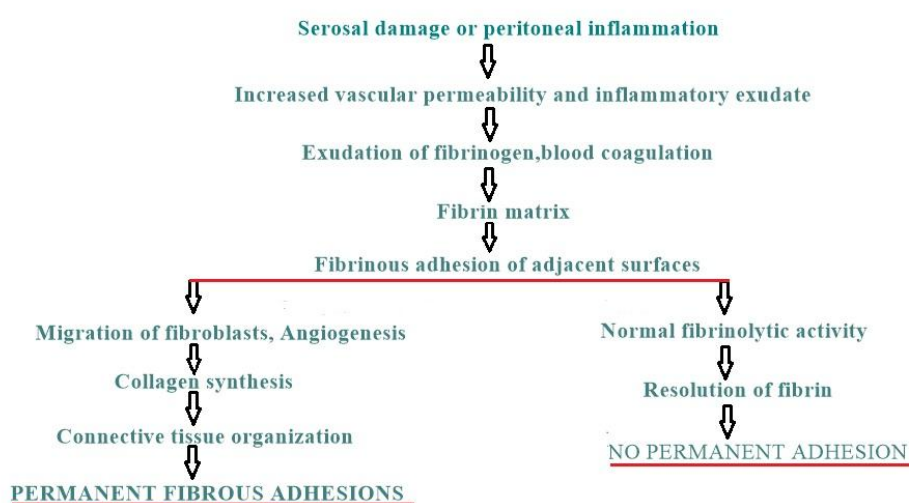
---

### **I. Introduction**

Intra-abdominal adhesions are almost inevitable after major abdominal surgery. Post operative intra-abdominal adhesions should be considered beneficial because they form in response to ischemia and provide an additional blood supply to compromised serosa and intestine. However, when fibrinous and omental adhesions are converted to permanent fibrous adhesions, clinical problems can be encountered (1). Enormous effort in clinical and laboratory research has been expended to elucidate the cause of intraperitoneal adhesions. A large volume of literature has been published and various agents or methods for the prevention and treatment of postoperative adhesions have been advocated, but few, if any, of the reports have been substantiated by other investigators or have been incorporated into a standardized approach to this problem (2-4). The most common cause of intraperitoneal adhesions is previous abdominal surgery, which accounts for 60-80% of all cases. Other causes are intra-abdominal inflammatory diseases and congenital abnormalities (5).

Peritoneal lesions caused by abrasion, ischemia, inflammation, desiccation, infection, thermal injury, and foreign bodies ( talc or starch from gloves, lint from sponges, suture material, toxic chemicals and prosthetic patches) are the origin of adhesions (6-12). Intraabdominal adhesions, which can begin forming within a few hours after an operation, represent one of the most common causes of intestinal obstruction (13). All adhesions do not cause intestinal obstruction. One patient with extensive adhesions may be completely asymptomatic throughout his lifetime while a single adhesion in another patient can lead to obstruction and strangulation of the bowel (2). Recurrent intestinal obstruction from adhesions present a difficult problem. Enterolysis alone is frequently followed by further obstructing adhesions, and multiple operations are common for obstruction (14). Several studies have reported the occurrence of postoperative intra-abdominal adhesions in 50%-95% of women undergoing gynecologic surgery (15-17). Baxter et al. (1) showed that clinically, the risk of postoperative intra-abdominal adhesions in the horse appears to be greater after small intestinal surgery, and adhesions usually involve the small bowel. Problems associated with postoperative adhesions could occur after other types of abdominal surgery in the horse (e.g., large intestinal, ovariectomy, cryptorchidectomy, umbilical hernia), but most likely would be less common. Therefore, the 22% incidence of clinical problems directly related to intra-abdominal adhesions after small intestinal surgery. It probably underestimates the total occurrence of adhesions after small intestinal surgery because equine intra-abdominal adhesions involving the large intestine, including the cecum, often do not result in clinical signs of abdominal pain. Therefore, the actual occurrence of postoperative intra-abdominal adhesions after small intestinal surgery or any abdominal surgery in the horse may be considerably higher than 22%. Repeat exploratory laparotomies in horse are associated with a higher incidence of intra-abdominal adhesions. Repeat abdominal surgery in the early postoperative period should be avoided in the horse if possible to minimize problems associated with intra-abdominal adhesions. However this is not always feasible because early postoperative ileus and small intestinal lesions necessitating additional surgery can portray similar clinical signs. To understand the action of different agents in the prevention of adhesions, it is necessary first to understand the pathogenesis of adhesion formation.

**Pathogenesis of adhesion formation:** The pathogenesis of adhesion between serosal surfaces is usually explained as follows: The peritoneal cavity contains a small amount of fluid between the parietal and visceral peritoneum. The cell count of this peritoneal fluid is less than 3000 cells/ml and consists mainly of macrophages and lymphocytes (18). The genesis of peritoneal adhesions includes capillary dilatation and increased capillary permeability as a nonspecific response to injury of peritoneal surfaces. Surgical trauma to the peritoneum causes a disruption of stromal mast cells, resulting in the release of vasoactive substances such as histamine and vasoactive kinins. These substances promote an increase in blood vessel permeability that leads to the escape of a serosanguineous exudate into the peritoneal cavity. Coagulation of this exudate causes adhesions of serosal surfaces within as little as 3 hr. Present within the fibrin mesh were cells of many types including polymorphonuclear leucocytes, macrophages, mesothelial cell (some partially detached), and occasional unidentified cell. This fibrin can either re-absorb completely, leaving a clear peritoneal cavity, or become organized by the ingrowth of fibroblasts to form established fibrous adhesions (Figure 1)(3,8,19,20). Normally, plasminogen activation from the mesothelial cells in the peritoneum leads to fibrinolysis and prevents adhesion formation. In the presence of inflammation or tissue ischemia, fibrinolysis may be inhibited because of decreased plasminogen activity, thereby facilitating the organization of fibrin exudate into fibrinous adhesions (18,21).



**Figure 1:** Pathogenesis of adhesion formation.

**Attempts to prevent adhesions have been approached from a number of different aspects, which can be classified as follows:**

*Prevention of fibrin deposition:* This has involved the use of anticoagulants such as sodium citrate, heparin (22), dicumarol, aprotinin (23). Aprotinin is a naturally occurring serine protease inhibitor that was isolated from bovine lung tissue. It inhibits kallikrein and plasmin. Its anti-inflammatory effects may lead to a decrease in adhesion formation (24). Noxytiolin (25). Its anti-adhesive effect may be due to its anticoagulant, cytotoxic or antibacterial properties, or perhaps to a combination of these factors. Dextran, polyethylene glycol 4000 (26,27), Povidone-Iodine (28,29). *Removal of fibrin exudate, by means of intraperitoneal lavage:* Enzymes such as pepsin, trypsin and papain and fibrinolytic agents such as streptocinase (30), actase and urokinase, hyaluronidase, pentoxifylline (31,32), plasmin, fibrinolysin, tissue plasmin activator, taurolidine (33-36). *Separation of surfaces:* Distention of the abdominal cavity with oxygen, phospholipids (10), stimulation of peristalsis with prostigmine or silicone solutions to prevent prolonged contact between adjacent loops of intestine (37,38), free grafts of omentum, tolmetin sodium (20), prosthetic mesh (40), Surgicel (41), interceed; is simple to use. Once applied correctly, it stays in place without the need to apply sutures. More importantly, it may be applied not only during laparotomy but also during laparoscopy, whereas it is extremely difficult to perform omental or peritoneal grafts in the course of laparoscopy (42), povidone-iodine (28,29), macromolecular solutions such as dextran 40, dextran 70 (16) and polyethylene glycol 4000 (26,27). Macromolecules are believed to have three principal modes of action in adhesion prevention. The first is through a prolonged increase in intraperitoneal fluid, due to their oncotic pressure, which floats tissues apart while healing occurs. Their large molecular size ensures that they are absorbed slowly from the peritoneal cavity and thus maintain this tissue separation during the critical time for adhesion formation. The second proposed mode of action of macromolecules is by promotion of non-adherent healing through polymer coating, or siliconization of the injured surfaces. Their third proposed action is a direct effect on enzymatic activity which may alter healing process. Polyethylene glycol 4000 also interferes with enzyme activity by altering enzyme

structure and creating a hydrophilic shell around the enzyme; this effect is greater on larger enzymes (26,27). *Inhibition of fibroblastic proliferation:* ACTH, cytotoxic drugs, dexamethasone, ibuprofen (43,44), oxyphenbutazone (35), vitamin E, selenium (45), 5-fluorouracil (46). Sodium hyaluronate/ carboxymethylcellulose (47). *Accelerating of wound healing and stimulating of epithelialisation:* Vitamine A, citral (48), promethazine (49). *Prevention of the complications of intestinal adhesions by control of their configuration:* Noble (50) introduced intestinal plication, whereby loops of intestine are fixed to neighboring loops in such a way as to prevent or decrease the possibility of torsion and subsequent obstruction. Childs and Phillips (51) presented a modification of the Noble operation. With long needles and heavy silk sutures the small intestines were arranged in the plicated position and secured by means of three or four mattress sutures through mesentery. Transmesenteric plication should be used for recurrent intestinal obstruction and should be considered when parietal or visceral peritoneal denuding has occurred secondary to enterolysis or extensive operative procedures (14). Recurrent adhesive small bowel obstruction is a difficult problem to manage; neither present conservative nor surgical management is consistently effective for either band or widespread adhesions. The commonest operation is “ simple” division of adhesions which is often unsuccessful in the long term because of adhesion reformation (27). It isn't possible adhesiolysis with drugs which of formation past a few month. Only is useful simple division with hand or scissors. Drugs used at the prevention of postoperative adhesions may be useful at the prevention of fibrinous adhesions and regression of fibrous adhesions which implying loose collagen (26).

It is frequently coincide with adhesions at the rumenotomies and operations of umbilical cord. It is made simple division of adhesions. But, this is increase formation of post operative intra-abdominal adhesions. For the presence of intra-abdominal adhesions during the operation is evidence of decreased fibrinolytic activity. Both simple division of adhesions and laparotomy are more decrease this activity. It have to be obtained precautions for prevent of reformation postoperative intraperitoneal adhesions after simple division of adhesions. Also, it is inevitable postoperative adhesions after laparotomies which is made at the area conditions (52,53).

Believed that laparoscopic adhesiolysis would be more effective in preventing reformation than adhesiolysis with laparotomy. Adhesiolysis for the advanced laparoscopic surgical techniques include scissor dissection, aquadissection, electrosurgery, laser and suturing. Aquadissection and scissors dissection are used in preference to thermal energy sources, scissors are the best instrument to use to cut avascular adhesions, congenital adhesions and peritoneal adhesions. Both lasers and electrosurgery are equally effective in adhesiolysis. Laser laparoscopic adhesiolysis is effective in reducing intraperitoneal adhesions (54).

## II. Conclusion

Many experimental methods have been studied in an attempt to decrease post-operative adhesions because of their importance (intestinal obstruction and infertility). Adhesions may be diminished in five ways: First, the initial injury can be minimized. Second, the coagulation of exudate can be prevented. Third, prolonged contact of surfaces can be reduced. Fourth, fibrin can be removed after it is formed, and fifth, fibroblast proliferation can be stopped or slowed. Laparoscopic adhesiolysis would be more effective in preventing reformation of adhesions than adhesiolysis with laparotomy.

## References

- [1]. GM. Baxter, TE. Broome and JN. Moore, Abdominal adhesion after small intestinal surgery in the horse. *Veterinary Surgery*, 18 (6), 1989, 409-414.
- [2]. JE. Connolly, and JW. Smith, The prevention and treatment of intestinal adhesions. *International Abstracts of Surgery*, 110(5), 1960, 417-430.
- [3]. H. Ellis, The causes and prevention of intestinal adhesions. *Brit. J. Surg*, 69, 1982, 241-243.
- [4]. HM. Seitz, JG. Schenker, S. Ebstein, CR. Garcia, Postoperative intraperitoneal adhesions: A double-blind assessments of their prevention in the monkey. *Fertil. Steril*, 24(12), 1973, 935-940.
- [5]. A. ArRajab, W. Mileski, JT. Sentementes, P. Sikes, RB. Harris and IJA. Dawidson, The role of neutrophils in peritoneal adhesion formation. *J. Surg. Res*, 61, 1996, 143-146.
- [6]. FO. Belzer, The role of venous obstruction in the formation of intra-abdominal adhesions: An experimental study. *Brit. J. Surg*, 54(3), 1967, 189-190.
- [7]. SAR. Cooke, and DG. Hamilton, The significance of starch powder contamination in the aetiology of peritoneal adhesions. *Brit. J. Surg*, 64, 1977, 410-412.
- [8]. H. Ellis, The cause and prevention of postoperative intraperitoneal adhesions. *Surg. Gynec. Obstet*, 133, 1971, 497-511.
- [9]. DG. Jagelman, and H. Ellis, Stach and intraperitoneal adhesion formation. *Brit. J. Surg*, 60(2), 1973, 111-114.
- [10]. SA. Müller, KH. Treutner, L.Tietze, M. Anurov, S. Titkova, M. Polivoda, AP. Oettinger, V. Schumpelick, Efficacy of adhesion Prevention and impact on wound healing of intraperitoneal phospholipids. *J. Surg. Res*, 96, 2001, 68-74.
- [11]. GB. Ryan, J. Grobety and G. Majno, Postoperative peritoneal adhesions. *Am. J. Path*, 65(1), 1971, 117-138.
- [12]. MA. Weibel, and G. Majno, Peritoneal adhesions and their relation to abdominal surgery. *Am. J. Surg*, 126, 1973, 345-353.
- [13]. NF. Ray, WG. Denton, M. Thamer, SC. Henderson and S. Perry, Abdominal adhesiolysis: Inpatient care and expenditures in the United States in 1994. *J. Am. Coll. Surg*, 186(1), 1998, 1-9.
- [14]. AT. Ferguson, VA. Reihmer and MR. Gaspar, Transmesenteric plication for small intestinal obstruction. *Am. J. Surg*, 114, 1967, 203-208.

- [15]. G. Holtz, Prevention and management of peritoneal adhesions. *Fertil. Steril*, 41, 1984, 497-507.
- [16]. DM. Magyar, MF. Hayes, NJ. Spirtos, ME. Hull and KS. Moghissi, Is intraperitoneal dextran 70 safe for routine gynecologic use. *Am. J. Obstet. Gynecol.*, 152(2), 1985, 198-204.
- [17]. TCM. Trimbos-Kemper, JB. Trimbos and EV. vanHall, Adhesion formation in tubal surgery: Results of the eight day laparoscopy in 188 patients. *Fertil. Steril*, 43, 1985, 395-400.
- [18]. A. Ar'Rajab. I. Dawidson, J. Sentementes, P. Sikes, R. Harris and W. Mileski, Enhancement of peritoneal macrophages reduces postoperative peritoneal adhesion formation. *J. Surg. Res*, 58, 1995, 307-312.
- [19]. LR. Bryant, Evaluation of the effect of fibrinolysin on intraperitoneal adhesion formation. *Am. J. Surg*, 106, 1963, 892-897.
- [20]. DS. Schade, and JR. Williamson, The Pathogenesis of peritoneal adhesions: An ultrastructural study. *Ann. Surg*, 167(4), 1968, 500-510.
- [21]. RF. Buckman, M. Woods, L. Sargent and AS. Gervin, A unifying pathogenic mechanism in the etiology of intraperitoneal adhesions. *J. Surg. Res*, 20, 1976, 1-5.
- [22]. JJ. Knightly, D. Agostino and EE. Clifton, The effect of fibrinolysin and heparin on the formation of peritoneal adhesions. *Surgery* 52 (1), 1962, 250-258.
- [23]. HL. Young, MH. Wheeler and D. Morse, The effect of intravenous aprotinin (trasylo) on intraperitoneal adhesion formation in the rat. *Br. J. Surg*, 68, 1981, 59-60.
- [24]. Y. Ozogul, A. Baykal, D. Onat, N. Renda and I. Sayek, An experimental study of the effect of aprotinin on intestinal adhesion formation. *Am. J. Surg*, 175, 1998, 137-141.
- [25]. OJA. Gilmore, and C. Reid, Noxytiolin and peritoneal adhesions formation. *Brit. J. Surg*, 63, 1976, 978-980.
- [26]. E. Karabulut, Tavsanlarda deneysel olarak olusturulan; intraabdominal adezyonların onlenmesinde polyethylene glycol ve dextran'ın karsilastirmali arastirilmesi. *F.U.Saglik Bil.Dergisi*, 9(2), 1995, 272-281.
- [27]. D. O'Sullivan, M. O'Riordain, RP. O'Connell, M. Dineen and MP. Brady, Peritoneal adhesion formation after lysis: Inhibition by polyethylene glycol 4000. *Br. J. Surg*, 78, 1991, 427-429.
- [28]. OJA. Gilmore, and C. Reid, Prevention of peritoneal adhesions by a new Povidone-Iodine/PVP Solution. *J.Surg.Res.* 25, 1978, 477-481.
- [29]. MK. Mazuji, and HA. Fadhli, Peritoneal adhesions prevention with povidone and dextran 75. *Arch. Surg*, 91, 1965, 872-874.
- [30]. DCO. James, H. Ellis, TB. Hugh, The effect of streptokinase on experimental intraperitoneal adhesion formation. *J. Path. Bact*, 90, 1965, 279-287.
- [31]. OR. Tarhan, I. Barut, R. Sutcu, Y. Akdeniz and O Akturk, Pentoxifylline, a methyl xanthine derivative, reduces peritoneal adhesions and increases peritoneal fibrinolysis in rats. *Tohoku . Exp.Med*, 209, 2006, 249-255.
- [32]. MMP. Reijnen, JFGM. Meis, VA. Postma and H. vanGoor, Prevention of intraabdominal abscesses and adhesions using a hyaluronic acid solution in a rat peritonitis model. *Arch. Surg*, 134, 1999, 997-1001.
- [33]. OR Tarhan, I Barut, and M Sezik, An Evaluation of Normal Saline and Taurolidine on Intra-Abdominal Adhesion Formation and Peritoneal Fibrinolysis. *Journal of Surgical Research* 144, 2008, 151-157.
- [34]. BWJ. Hellebrekers, TCM. Trimbos-Kemper, JBMZ. Trimbos, JJ. Ermeis and T. Kooistra, Use of fibrinolytic agents in the prevention of postoperative adhesion formation. *Fertil Steril*, 74(2), 2000, 203-212.
- [35]. BML. Kapur, SM. Gulati, JR. Talwar, Prevention of reformation of peritoneal adhesions. Effect of oxyphenbutazone. proteolytic enzymes from carica papaya, and dextran 40. *Arch. Surg*, 105, 1972, 761-764.
- [36]. SK. Nair, IK. Bhat and AL. Aurora, Role of proteolytic enzyme in the prevention of postoperative intraperitoneal adhesions. *Arch. Surg*, 108, 1974, 849-853.
- [37]. Y. Aboulafia and WZ. Polishuk, Prevention of peritoneal adhesions by silicone solution. *Arch Surg*, 94, 1967, 384-387.
- [38]. HS. Sachdeva, LV. Gutierrez and AG. Cox, Silicone fluid and steroids in the prevention of adhesions. *Brit. J. Surg*, 59(5), 1971, 382-384.
- [39]. EK. LeGrand, KE. Godgers, W. Girgis, K. Struck, JD. Campeau, GS. DiZerega, TC. Kiorpes, Efficacy of Tolmetin Sodium for adhesion prevention in rabbit and rat models. *J. Surg. Res*, 56, 1994, 67-71.
- [40]. PK. Amid, Intraabdominal adhesions to prosthetic mesh. *J. Am. Coll. Surg*, 191(3), 2000, 342-343.
- [41]. B. Larsson, H. Nisell and I. Granberg, Surgicel an absorbable hemostatic material in prevention of peritoneal adhesions in rats. *Acta Chir. Scand*, 144, 1978, 375-378.
- [42]. TC. Li and ID. Cooke, The value of an absorbable adhesion barrier, interceed, in the prevention of adhesion reformation following microsurgical adhesiolysis. *Br J Obstet Gynaecol*, 101, 1994, 335-339.
- [43]. AA. Luciano, KS. Hauser and J. Benda, Evaluation of commonly used adjuvants in the prevention of postoperative adhesions. *Am. J. Obstet. Gynecol.*, 146(1), 1983, 88-92.
- [44]. AM. Siegler, V. Kontopoulos and CF. Wang, Prevention of postoperative adhesions in rabbits with ibuprofen, a nonsteroidal anti-inflammatory agent. *Fertil. Steril*, 34(1), 1980, 46-49.
- [45]. Z. Alkan, A. Kaya, H. Bilgili, A. Bumin and T. Guvenc, Tavsanlarda intraabdominal adezyonların onlenmesinde antioksidan maddelerin (vitamine E, selenyum) kullanilmasi uzerine deneysel calismalar. *Veteriner Cerrahi Kongresi* 16-18 Haziran, Urgup, 1994, 32
- [46]. LI Goldman, and GP. Rosemond, 5-Fluorouracil inhibition of experimental peritoneal adhesions. *Am. J. Surg*, 113, 1967, 491-493.
- [47]. Corrales F, Corrales M and Schirmer CC, Preventing intraperitoneal adhesions with vitamin E and sodium hyaluronate/carboxymethylcellulose. A comparative study in rats. *Acta Cirúrgica Brasileira*, 23(1), 2008, 36-41.
- [48]. AA. Demetriou, E. Seifter and SM. Levenson, Effect of vitamin A and citral on peritoneal adhesion formation. *J. Surg. Res*, 17, 1974, 325-329.
- [49]. RL. Replogle, R. Johnson and RE. Gross, Prevention of postoperative intestinal adhesions with combine promethazine and dexamethasone therapy: Experimental and clinical studies. *Ann. Surg*, 163(4), 1966, 580-588.
- [50]. TB. Noble, Plication of small intestine as prophylaxis against adhesions. *Am. J. Surg*, 35, 1937, 41-44.
- [51]. WA. Childs, and RB. Phillips, Experience with intestinal plication and a proposed modification. *Ann. Surg*, 152, 1960, 258-265.
- [52]. T. Durgun, E. Karabulut, S. Unsaldi and MC. Han, Buzagaların gobek enfeksiyonlarında postoperatif adezyonların onlenmesinde Polyethylene Glycol'un kullanilmasi. *F.U. Saglik Bil. Dergisi* 11(2), 1997, 307-310.
- [53]. T. Durgun, E. Karabulut, S. Unsaldi and MC. Han, Sigirlarda rumenotomilerde postoperatif adezyonların onlenmesi amaciyla polyethylene glycol'un kullanilmasi. *F. U. Saglik Bil. Dergisi*, 11(2), 1997, 311-315.
- [54]. Karabulut, E. and T. Durgun, Laparoskopik cerrahide adezyolizis. *Veteriner Cerrahi Dergisi*, 7(3-4), 2001, 78-82.