

Chemical Castration of Adult and non-Adult Male Dogs with Sodium Chloride Solution

Ibrahim Canpolat¹, Enis Karabulut¹, Yesari Eroksuz²

¹Department of Surgery, Veterinary Faculty, Firat University, Elazig, Turkey

²Department of Pathology, Veterinary Faculty, Firat University, Elazig, Turkey

Abstract: This study evaluated intra-testicular injection of sodium chloride for chemical-castration in 12 mix bred dogs (6 adult and 6 non-adult). The sodium chloride at 20% concentration per testis were injected intratesticularly until tension occurs and the testicles were removed with the open surgical technique about 30 days for histopathologic evaluation. Testicular swelling was evident in both group dogs following injection and reached peak within 48 hours. While testicular volume decreased significantly ($P < 0.05$) in both group after 2-4 weeks. The testicles underwent atrophy at the 30th day in non-adult group with no marked alteration in adult group. Though only 3 non-adult dogs were sterile, other adult dogs maintained androgenesis. It was concluded that intra-testicular injections of sodium chloride at 20% concentration administration may not be accepted as a suitable alternative to the open surgical technique for castration in adult dogs but could be used as a preferable treatment option non adult dogs.

Keywords: Chemical, castration, dog, sodium chloride.

I. Introduction

Chemical sterilization is tried on the males of some species including monkeys, hamsters, rabbits, rats and dogs by intratesticular injection of several agents such as ferric chloride (1), danazol (2), BCG (3), zinc tannate (4), glycerol (5, 6), DBCP (7), lactic acid (8), zinc arginine (9), sodium fluoride (10), formaline (11) and calcium chloride (12, 13, 14), zinc gluconate (15), chlorhexidine digluconate (16), hypertonic saline (17, 18). Yet, an effective chemical sterilizing agent has not been established. The purpose of the study was to determine the efficacy of intratesticular injection of sodium chloride at 20% concentration on chemosterilization outcome of the young and adult male dogs.

II. Material and Methods

All experimental procedures were reviewed and approved by the Firat University of Animal Hospital Committee. In the study, 6 adult (22-45 kg, 2-4 years old) and 6 non-adult (3-8 kg, 1-3 months old) male dogs were used. They were divided adult and non-adult into two groups. The hypertonic solution was prepared by dissolving sodium chloride (200 g/L) in pure water. After dilution, the 20% NaCl solution was autoclaved in 100 mL glass bottles and stored at 4 °C until use. To perform intra-testicular injection or surgical castration, animal's scrotal skin were disinfected using iodine solution. Both procedures were performed under general anesthesia (propofol 6ml/kg and %3 sevoflurane). The sodium chloride at 20% solution were injected intratesticularly using a needle until tension occurs both groups. Trans-scrotal testicular ultrasonography was performed with 7.5-5 Mhz linear probe (Pie medical, ScanVet-200) prior to the intratesticular injection and once a day for week following intratesticular injection and then one week intervals up to the end of the study. During this examination, the ultrasonographic appearance of a testis was evaluated and its height (h), width (W) and length (l) was measured. The volume of the testis was estimated using $\text{Volume} = (\pi/6) \times (w \times h \times l)$ equation. The testes all dogs removed surgically at 30 days and fixed and prepared for histologic evaluation with routine processing procedures.

Histopathological method: After 60th day of the procedure, testicles were collected and fixed in 10% formaline and embedded in paraffine using the standard procedure. Paraffine blocks, sectioned in 5 micrometer mounted on slides and stained with hematoxyline and eosine. Statistical analyses was performed paired sample t-test. All data are presented as mean \pm SEM (Standard Error of the Mean). The level of significance was set at $p < 0.05$.

III. Result and Discussion

Testicular swelling was evident in all dogs of both groups following injection and reached peak within 48 hours. The testicular volume decreased significantly ($P < 0.05$) in non-adult dogs after 3 weeks, no significant change occurred in adult dogs ($P > 0.05$). Ultrasonographic examination one day after drug injection revealed the testicular tissue of all animals of both groups to present diffuse echotexture and increased echogenite. The

necrotized regions were differentiated ultrasonographically from the normal testicular tissue with hypoechoic appearance. The testicles underwent atrophy at the 30th day in 3 non-adult dogs but marked alteration was not observed in adult dogs (Figure 1). In a non-adult cases, testicular swelling was associated with fistula and sloughing of the scrotal skin. At necropsy, their testicular tissues were found to have totally been necrotized and obtained a muddy texture. These problems were not recognized in any other cases. In adult cases macroscopically restricted necrotized region showing dark area (Figure 2). In dogs younger than 6 months old, gross appearance of the testes received 20% hypertonic saline solution became completely necrotic with demarcation line at the end of 2 days. At the end of 60 days; testicles were hard in consistency and smaller in appearance. Histopathological examinations indicated that focal coagulation necrosis in testicular tissue together with diffuse and severe degenerative changes in seminiferous tubuli (Figure 3). There was sparse Leydig cell in tubular lumen.

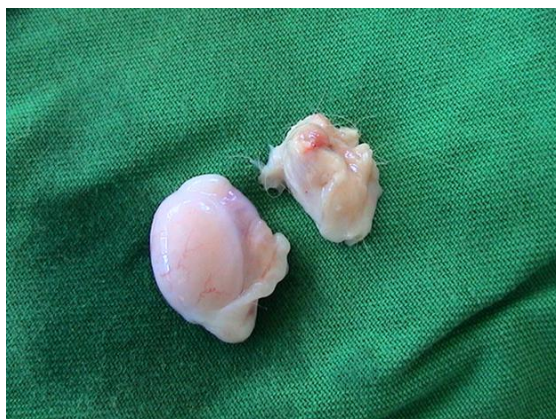

Figure 1: Severe atrophy and normally testes in non-adult dogs.

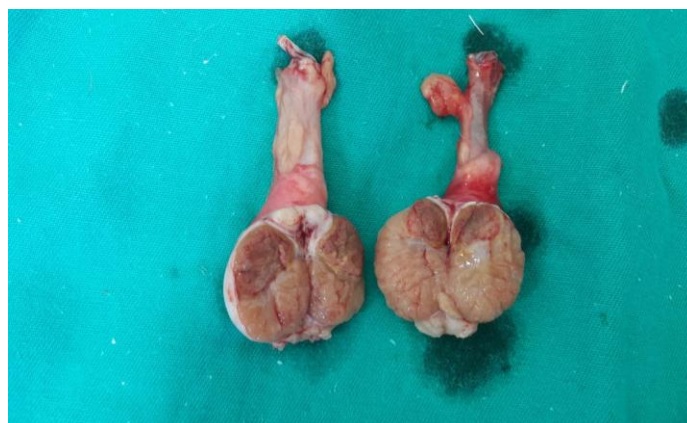

Figure 2: Appearance of necrotic area in adult dogs (dark areas).

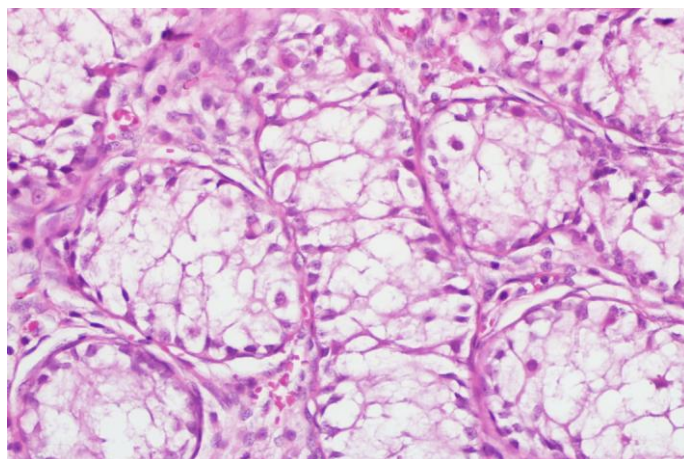


Figure 3: Severe atrophy in seminiferous tubuli.

Chemical castration was experimented in males dogs by intratesticular injection of some agents such danazol (2), zinc arginine (9), glycerol (6), ethanol (19) formaline (11) and calcium chloride (13, 14), zinc gluconate (15), chlorhexidine digluconate (16). Intratesticular injection of hypertonic saline used for animal castration model in male rats (18, 20) but It is not used dog. In this study hypertonic saline (20% NaCl) used for chemical castration model in adult and non adult male dogs. Hypertonic saline is a solution that is inexpensive and easy to administrate. In a study 20% hypertonic saline solution was injected bilaterally into the rat testes at different areas with a total amount of about 0.5 to 1 cc in each testis. Reported that the coagulation necrosis was observed in all testes (18). Kwat et al. (2013) revealed that severe degenerative changes in testicular seminiferous tubules and massive infiltration of immune cells in hypertonic saline group. Additionally researchers indicated that “intratesticular hypertonic saline injection seems to be an alternative method in the future to its rivals such as orchietomy and medical castration” but that further laboratory work would be required to ascertain the potential utility of this approach in dogs (18). In this study, it was observed that 20% sodium chloride could be used for chemical castration in young dogs.

IV. Conclusion

It was suggested that intra testicular injection of hypertonic saline could be an effective method for nonsurgical sterilization of the non adult male dogs but not adult dogs.

References

- [1] A.B. Kar, V.P. Kamboj and A. Goswami, *J Rep and Fert*, 9, 1965, 115-117.
- [2] V.P. Dixit, N.K. Lohiya, M. Arya and M. Agrawal, Chemical sterilization of male dogs after a single intra-testicular injection of "Danazol", *Folia Biol (Krakow)*, 23(3), 1975, 305-310.
- [3] R.P. Das, A.S. Mustafa and G.P. Talwar, Atrophy of seminiferous tubules of mouse testes after intratesticular injection of BCG and their regeneration, *Arch Androl*, 9(3),1982, 244-250.
- [4] M.S. Fahim, Z. Fahim, J.M. Harman, Chemical sterilization in the male part I: rats. *Arch Androl* 9(3), 1982, 261-265.
- [5] G.F. Weinbauer, M.M. Galhotra, E. Nieschlag, Focal testicular destruction following intratesticular injection of glycerol in rats, *Int J Androl*, 8(5), 1985, 365-375.
- [6] H.M. Immegart, W.R. Threlfall, Evaluation of intratesticular injection of glycerol for nonsurgical sterilization of dogs, *Am J Vet Res*, 61(5), 2000, 544-549.
- [7] D. Shemi, Z. Marx, J. Kaplanski, G. Potashnik and U.A. Sod-Moriah, Testicular damage development in rats injected with dibromochloropropane (DBCP). *Andrologia* 20(4), 1988, 331-337.
- [8] G. Fordyce, P.B. Hodge, N.J. Beaman, A.R. Laing, C. Campero and R.K. Shepherd, An evaluation of calf castration by intratesticular injection of a lactic acid solution, *Aust Vet J*, 66(9),1989, 272-276.
- [9] M.S. Fahim, M. Wang, M.F. Sutcu, Z. Fahim and R.S. Youngquist, Sterilization of dogs with intra-epididymal injection of zinc arginine, *Contraception* 47(1),1993, 107-122.
- [10] R.L. Sprando, T.N. Black, M.J. Ames, J.I. Rorie and T.F. Collins, Effect of intratesticular injection of sodium fluoride on spermatogenesis, *Food Chem Toxicol*, 34(4), 1996, 377-384.
- [11] B. Bakir, F. Gulyuz, F. Karaca, H. Yuksel, A. Sahin and B.A. Uslu, Chemical castration in dogs. *YYU J Healthy Sciences*, 8(1-2), 2002, 6-9.
- [12] A.B. Kar, Chemical sterilization of male rhesus monkeys. *Endocrinology*, 69, 1961, 1116-1119.
- [13] P.K. Samanta, Chemosterilization of stray dogs, *Indian Journal of Animal Health*, 37(1), 1998, 61-62.
- [14] K. Jana, P.K. Samanta and D. Ghosh, Dose dependent response to an intratesticular injection of calcium chloride for induction of chemosterilization in adult albino rats, *Vet Res Commun*, 26(8), 2002, 651-673.
- [15] F.R. Soto, W.G. Viana, G.C. Mucciolo, F.Y. Hosomi, C.L. Vannucchi, C.P. Mazzei, A.R. Eyherabide, C. de Fatima Lucio, R.A. Dias and S.S. de Azevedo, Evaluation of efficacy and safety of zinc gluconate associated with dimethyl sulphoxide for sexually mature canine males chemical neutering, *Reprod Domest Anim*, 44(6), 2009, 927-931.
- [16] G. Aiudi, F. Silvestre, R. Leoci and G.M. Lacalandra, Single Testicular Injection of Chlorhexidine Solution as Chemical Sterilant in Dogs, 4th International Symposium on Non-Surgical Contraceptive Methods of Pet Population Control, Dallas, USA, 2010.
- [17] E. Heath, R. Arowolo, The early histopathologic effects of intratesticular injection with hyperosmolar glycerol, glucose or NaCl solutions, *Andrologia* 19(6), 1987, 654-661.
- [18] L. Emir, M. Dadali, M. Sunay, D. Erol, M. Caydere and H. Ustun, Chemical castration with intratesticular injection of 20% hypertonic saline: a minimally invasive method, *Urol Oncol*, 26(4), 2008, 392-396.
- [19] I. Canpolat, S. Bulut, C. Gunay, H. Eroksuz and S. Gur, An evaluation of the outcome of bull castration by intra-testicular injection of ethanol and calcium chloride, *Revue Med Vet*, 157, 2006, 420-425.
- [20] B.K. Kwak and S.H. Lee, Intratesticular injection of hypertonic saline: non-invasive alternative method for animal castration model, *Dev Reprod*, 17(4), 2013, 435-440.