

Investigating The Respiratory Health Benefits Of Essential Oil Combination Product Resporan In Broiler Chickens Exposed To Mycoplasma Infection

Dr. Deepak Sumbria¹, & Dr. Nitin Singh²

¹ Ph.D. Veterinary Parasitology, Post Doc University Of Tennessee, Knoxville, Usa

² M.V.Sc. Veterinary Pathology, State Veterinary Hospital, S. Khadkhadi, Saharanpur (U.P.) India

Abstract

This study aimed to assess the efficacy of resporan a product produced by rivansh animal nutrition pvt ltd. In protecting the respiratory system of broiler chickens challenged with respiratory distress. Resporan is essential oil containing product which contains essential oil such as eucalyptus & menthol etc. One hundred and five one-day-old chicks were randomly allocated into three groups: group a (.), group b (treated with resporan and mycoplasma gallisepticum challenged), and group c (control group not challenged with mycoplasma gallisepticum and not treated with resporan). At one week of age, birds in groups a and b were intra-tracheally challenged with mycoplasma gallisepticum strain, while group b received oral administration of resporan for six days, starting from the 8th to the 13th day of age. Tracheal and lung samples were collected for histopathological examination from day 9th to 14th and day 28th of age. In mg-challenged birds (group a), histopathological analysis revealed mucosal hyperplasia, mucus accumulation, tracheal deciliation, inflammatory cell infiltration, and goblet cell hyperplasia in tracheal tissues, along with congestion and pneumonic foci in lung tissues. Conversely, birds treated with resporan and challenged with mycoplasma gallisepticum (group b) exhibited a significant reduction in histopathological lesions in tracheal and lung tissues. Resporan demonstrated efficacy in alleviating respiratory issues, suggesting its potential for use as both prophylactic and supportive treatment, in combination with antibiotics, for mycoplasma gallisepticum infections.

Keywords: mycoplasma gallisepticum, pcr, resporan, rivansh animal nutrition histopathological examination

Date of Submission: 14-03-2024

Date of Acceptance: 24-03-2024

I. Introduction

Mycoplasma gallisepticum poses a significant threat to poultry health, being among the most pathogenic avian mycoplasmas known to cause respiratory infections. The resulting chronic respiratory disease (crd) in chickens often leads to substantial economic losses within the poultry industry. Clinical signs of avian mycoplasmosis include sneezing, coughing, respiratory rales, ocular and nasal discharge, alongside reduced feed intake and increased morbidity. Concurrent infections with bacteria or viruses exacerbate the severity of mycoplasma infections, frequently resulting in elevated mortality rates among affected birds.

Mycoplasma gallisepticum primarily targets mucosal membranes within the respiratory tract, conjunctiva, and sinuses upon infection, with the upper airways and trachea serving as favored sites of colonization for most mycoplasma gallisepticum strains.

Resporan, a natural herbal product comprising essential volatile fatty acids (eucalyptus oil, mentha, menthol, camphor) and herbal essences, emerges as a potential intervention against mycoplasma infections. Its formulation, enriched with eucalyptus oil and menthol, boasts antibacterial, anti-inflammatory, antiseptic, and antioxidant properties. Resporan has demonstrated effectiveness in preventing respiratory disease complexes in poultry production, promoting performance enhancement, and fortifying the immune system.

This study aims to evaluate the therapeutic potential of resporan in alleviating the respiratory impacts of mycoplasma gallisepticum infection in treated groups. Gross and histopathological evaluations will be conducted to assess resporan efficacy in mitigating mg-induced respiratory diseases in poultry.

II. Materials And Methods

One hundred and twelve samples, including lung and trachea specimens, were collected from freshly deceased and slaughtered broiler chickens displaying respiratory symptoms (such as watery to mucoid nasal discharge, sneezing, gasping, tracheal rales, and conjunctivitis) in various locations across assiut. The chickens, aged between 20 to 35 days, had not been vaccinated against mycoplasma gallisepticum.

One hundred and five one-day-old broiler chicks (cobb 500) with an average body weight of 40 grams were obtained from local hatchery of haryana, and housed in well-isolated floor pens under hygienic conditions. The chicks were fed ad libitum on commercial broiler ration

Experimental design:

The broiler chicks were randomly divided into three equal groups (35 chicks per group). Group a was challenged with mycoplasma gallisepticum, group b received resporan treatment in addition to mg challenge, and group c served as the control group without mg challenge or resporan treatment. At one week of age, groups a and b were intra-tracheally challenged with mg strain, while group b received resporan treatment. Resporan was administered orally for 6 days, starting from the 8th to the 13th day of age, with a dosage of 0.25 ml/1000 ml of drinking water, twice in day, at a volume of 1 ml per bird per administration.

Histopathological examination

Tracheal and lung samples were collected from chickens at various time points (9th to 14th day of age and 28th day of age) for histopathological examination.

III. Results

Clinical findings in infected group (a) (challenged group):

Chicks within the infected group displayed clinical symptoms characterized by dullness, depression, ruffled feathers, coughing, sneezing, nasal discharges, and open-mouth breathing accompanied by moist rales.

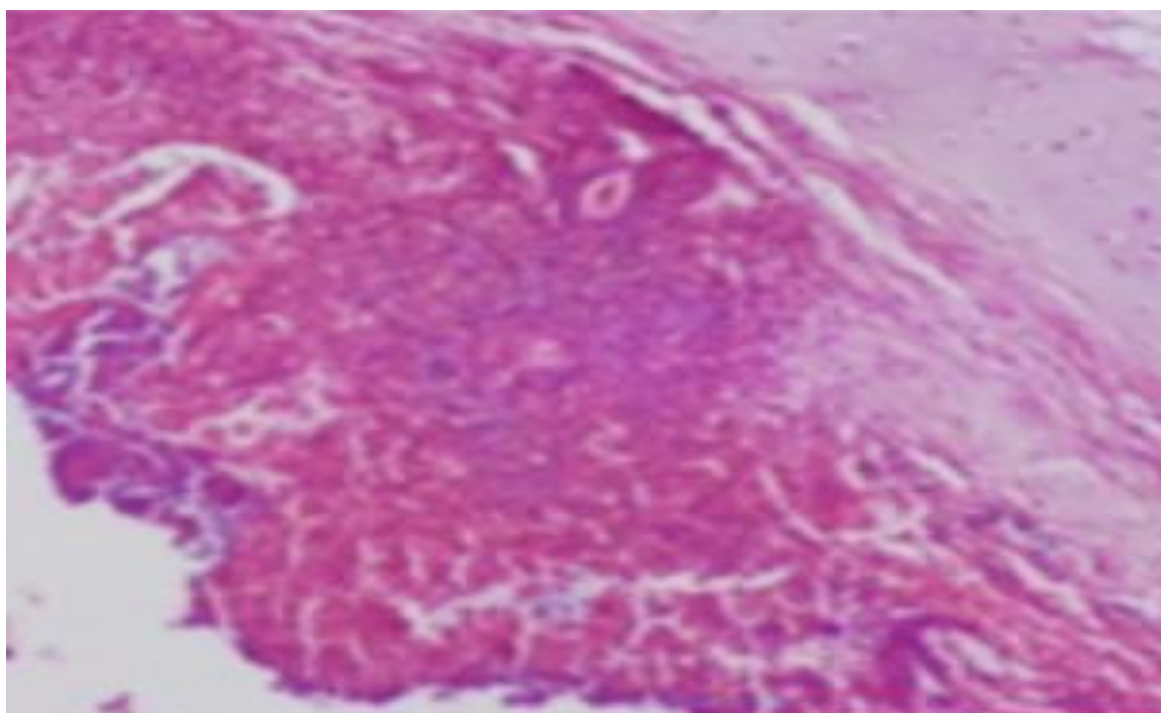


Figure: lung tissue displaying infiltration of lymphocytes and plasma cells.

Findings of group (b)

Contrarily, in group (b), which received treatment with resporan, the trachea showed no evidence of congestion or haemorrhages. Lung examination revealed a normal coloration with no signs of congestion. Additionally, the air sacs appeared normal, with thin walls and no cloudiness observed.

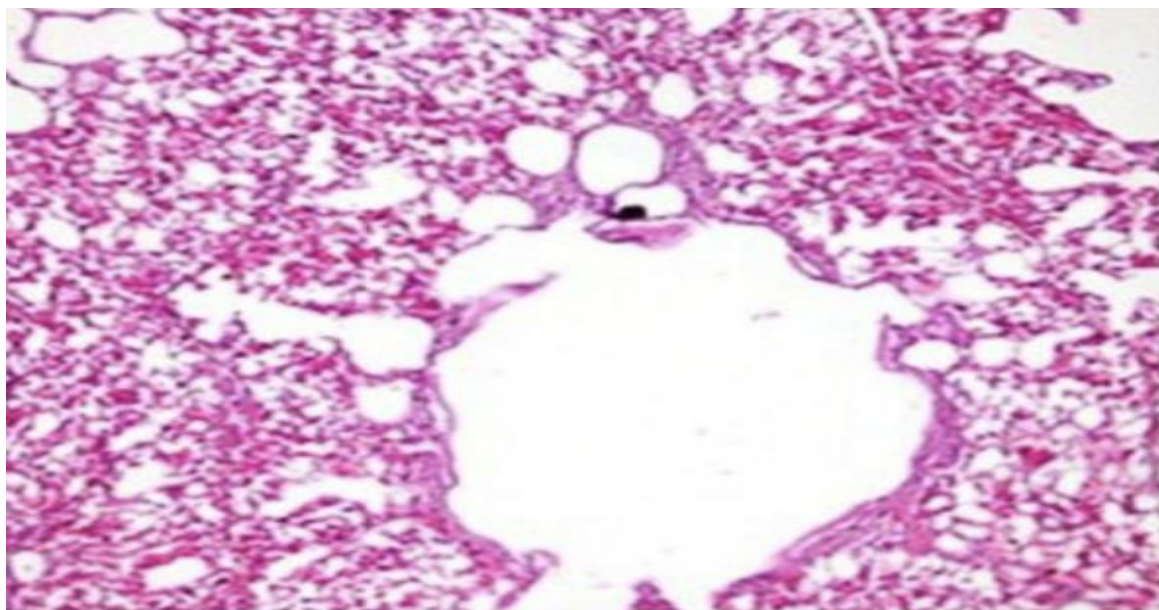


Figure: illustration of the treatment group b, depicting the typical parenchyma of parabronchus and air capillaries, exhibiting no signs of pathological alterations.

IV. Discussion

In the experimental trial assessing the effect of resporan in reducing mycoplasma infection lesions, birds in the challenged group (a) displayed clinical signs of respiratory distress, while post mortem examination revealed significant pathological changes in the trachea, lungs, and air sacs. These findings align with previous studies.

The mechanism underlying the relief of respiratory symptoms by volatile oils, such as those present in resporan, involves thinning of mucus in the respiratory tract, facilitating the outward flow of microorganisms and protecting cilia from damage. These findings are supported by previous studies

The observed improvements in group b may be attributed to the liquefaction and loosening of respiratory exudates by volatile oils, leading to improved breathing and increased feed intake. Resporan treatment also provided partial relief from lung histopathological lesions.

Acknowledgment

The authors express gratitude to rivansh animal nutrition pvt ltd & govindnandsagar herbal farm staff for their support during the research.

References

- [1] Ahmed, N.A.M. (2005). "Experimental Pathological Studies On Some Drugs Of Quinolones Group In Broiler Chicks." M.V.Sc. Thesis, Pathology Dept., Fac. Vet. Med., Zag. Univ.
- [2] Bancroft, J.D. And Stevans, A. (1993). "Theory And Practice Of Histologic Techniques." 3rd Ed. Long Man Group Limited. Pp. 113-305.
- [3] Barbour, E.K., Dankar, S., & Jaber, L. (2005). "Essential Oils Of Eucalyptus And Peppermint."