

Stenosis of the large intestine in a dog (A case report)

Kamal M. Alsaad And Abdulbari A. Alfaris

Department of Internal and Preventive Medicine, Department of Surgery and Obstetrics,
College of Veterinary Medicine, University of Basrah, Iraq.
Corresponding author: *Kamal M.Al Saad

Abstract: A male, Mullinoise breed, police (K9) dog, 30 kg weight and of 4 years old, had been brought to the Veterinary Clinical Hospital, College of Veterinary Medicine, University of Basrah, Iraq, with patient history and signs of anorexia, discomfort, intermittent diarrhea. On clinical examination, the diseased dog exhibited different clinical manifestations such as Abdominal type of respiration, Colicky pain and looked at his flank some times, Moderate degree of dehydration with sunken eyes, and Edema of hind legs is obvious with pits on pressure. Moreover, the diseased dog shows mild elevation in body temperature, respiratory and heart rate with mild anemia, However, electrolyte disturbances have been indicated reflected with hypernatremia and hyperkalemia. Furthermore, Hypoproteinemia was also registered. Besides, A latero-medial radiograph shows clear intestinal stenosis of a part of the large intestine of the disease dog. It could be concluded that Intestinal obstruction, complete or partial, may often lead to severe consequences in the sick animal, including unwanted clinical signs that often end in the death of the affected animal. Consequently, it must be emphasized to monitor animals that suffer from symptoms to speed up the early diagnosis of the disease.

Keyword: Dog, large intestine, Stenosis, Iraq.

Date of Submission: 14-04-2021

Date of Acceptance: 28-04-2021

I. Introduction

Intestinal obstruction in dogs refers to complete or partial blockage of fluid and food flow through the small and/or large intestines. This is somewhat common in dogs especially those who indiscriminate eaters. During obstruction, the blood supply to the gastrointestinal tract can become compromised, leading to necrosis (death) of intestinal tissue and possible perforation. Therefore, The bacteria from the bowels can spill and invade the abdominal cavity causing septic peritonitis. Obstruction can be deadly if not caught and treated early. Emergency surgery is often required to remove the obstruction and any dead tissue(1).

Large bowel disorders are common in dogs. These disorders can usually be managed very successfully. It is useful in any patient with diarrhea to begin by attempting to differentiate between the primarily small bowel and large bowel diarrhea, based on presenting signs and characteristics of the stool. Tests and treatment often vary for small and large intestinal disorders, making this initial characterization very important. Because large bowel-type problems occur so commonly, It often begins by asking questions relative to this area of the intestinal tract when presented with a patient with diarrhea. Specifically, the presence or absence of mucus, fresh blood, straining, and any change in frequency of defecation are discussed(2).

The large intestine of the dog has evolved to serve two major functions, extraction of water and electrolytes from the fluid contents of the lumen and control of defecation. The large intestine accomplishes these functions by regulating fluid transport, bacterial fermentation, motility, immune surveillance, and blood flow. Sodium and water absorption serve to dehydrate the feces before defecation, mucus glycoproteins serve to trap bacterial pathogens and prevent bacterial translocation, epithelial cells, lymphocytes, plasma cells, macrophages, and dendritic cells serve to regulate the bacterial flora and the immune response to microbes, and motility serves to facilitate storage or defecation of feces. Perturbations in any of these functions may result in the problems of diarrhea, constipation, or systemic inflammatory response syndrome (1,3).

The aim of this case report is a presenting a clinical case of a dog suffering from bowel obstruction detected at Basrah, Iraq.

II. Case Presentation

Animal history and presentation:-

A male, Mullinoise breed a police (K9) dog, 30 kg weight and of 4 years old, had been brought to the Veterinary Clinical Hospital, College of Veterinary Medicine, University of Basrah, Iraq, with patient history and signs of anorexia, discomfort, intermittent diarrhea and edema of lower legs.

Physical and laboratory examination:-

1-Complete physical examinations were performed for the diseased animal and included measuring the body temperature, respiratory and heart rate, as well as a physical examination of the kidneys, liver, and mucous membranes lining the eyes, Moreover, Auscultation of the lung and heart was also performed using the stethoscope.

2-Blood sample was aspirated from a cephalic vein using for complete blood picture (EDTA sample) (Automatic digital cell counter from Beckman USA) and the remaining used for extraction of serum for evaluation of Total protein, Sodium and potassium according to manufacture instruction of (Roche Diagnostics, Indianapolis, GMBH, Germany).

3- Fecal samples were screened for parasitic load, if any, using standard techniques. (4)

4-Radiographic examination:- A latero-medial view of the abdominal part using an X-ray machine (from Co-ray / USA) was taken under exposure factors (45kV).

III. Results

The diseased dog shows different clinical manifestations which are illustrated in **Table 1**.

Table 1. The clinical manifestations of a diseased dog

No	Clinical signs description
1	Abdominal type of respiration
2	The animal feels discomfort/ Fig 1 .
3	Colicky pain and looked at his flank some times
4	A moderate degree of dehydration (4-8 / second when applying skin ford test) with sunken eyes. Fig 2 .
5	Edema of hind legs is obvious with pits on pressure. Fig 3 .



Fig 1: The animal feel discomfort




Fig 2: Dehydration reflected with sunken eyes

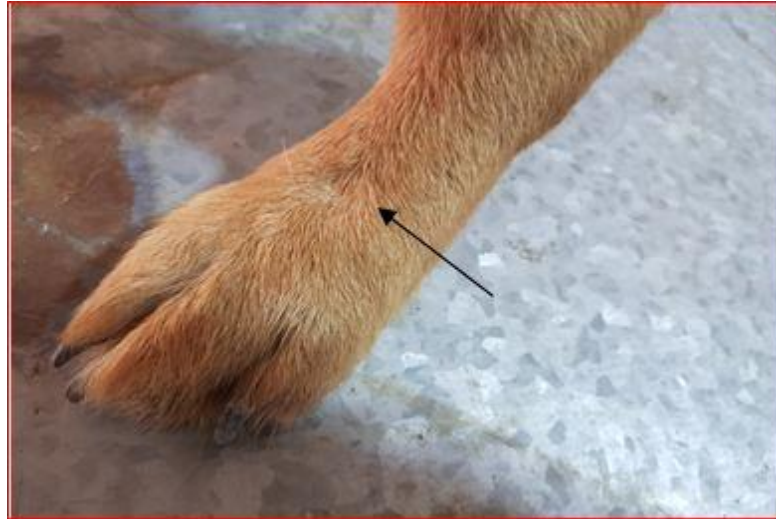

Fig 3: Edema of hind legs is obvious with pits on pressure

The vital signs of the diseased dog show, body temperature (39.4C), the heart rate were 132/ min, respiratory rate of 40/ mint. **Table 2.** Besides, examination of blood parameters indicates mild anemia. **Table 3.** Moreover, Biochemical changes reveal Hypoproteinemia, Hyponatremia, and Hyperkalemia in disease dogs **Table 3.**

Table 2: The Vital signs of the diseased dog

Parameters	Diseased animal (dog)	The normal reference*
Body temperature / C	39.4	37.5-39.2
Heart rate/min	132	70-120
Respiratory rate/ min	40	15-30

**Ettinger and Feldman, 2005(5)*

Table 3: Hematological parameters of the diseased dog

Parameters	Diseased animal (dog)	The Normal Reference*
RBC x 10 ⁶	4.2	4.8-9.3
Hb g/dl	10.5	12.1-20.3
PCV %	29	37-55
TLC x 10 ³	10.3	4.0-15.5
Lymphocyte %	29	12-30
Neutrophils %	60	66-77
Eosinophils %	4	2-12
Monocytes %	7	3-10
Basophils %	0	0.5-0.7
Total platelet counts x10 ³	248	170-400

**Ettinger and Feldman, 2005(5)*

Table 4: Biochemical analysis of the diseased dog

Parameters	Diseased animal (dog)	The normal reference*
Total protein g/dl	4.4	5.1-7.8
Sodium /mEq/l	195.15	141-146
Potassium mEq/l	33.76	4.37-5.65

**Ettinger and Feldman, 2005(5)*

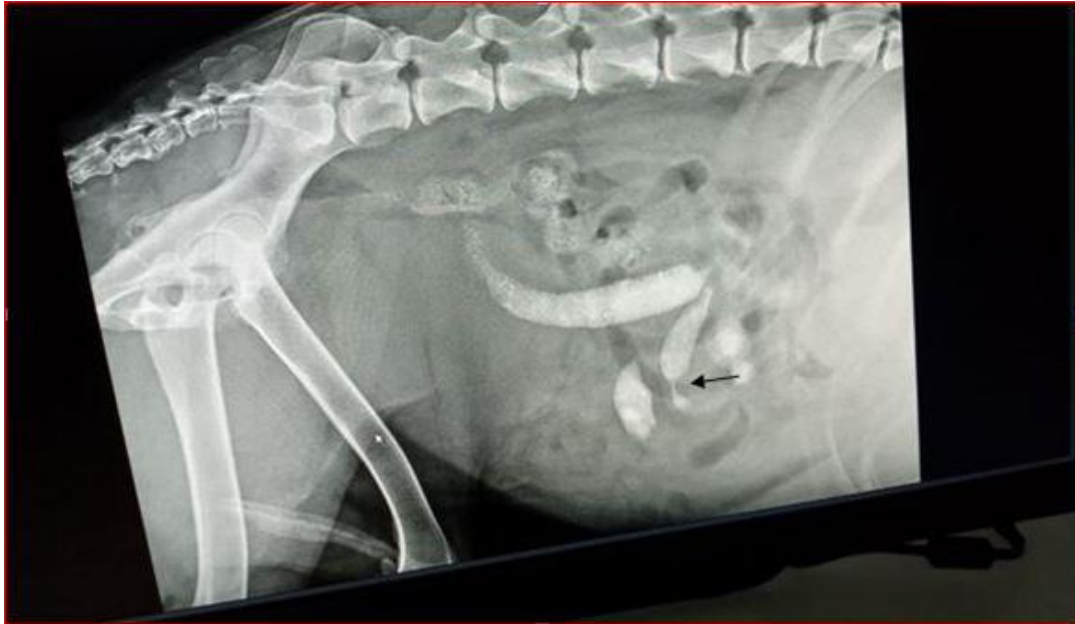

Fig 4: Abdominal radiograph(A latero-medial view) of the dog for which intestinal stenosis of a part of the large intestine was noticed (arrow)

IV. Discussion

A bowel obstruction, also known as a gastrointestinal blockage, is a common canine problem. Dogs are naturally curious, and many have a desire to eat or chew almost anything. Most dog owners are aware of this issue, whether or not their dog has experienced it (6). All dogs are at risk, but young dogs are especially vulnerable. Puppies tend to be more eager to put every object into their mouths, often because they are often teething and are looking for something to chew(7).

In general, A bowel obstruction is a complete or partial blockage in the stomach or intestines that prevents solids or liquids from passing through the gastrointestinal tract. This blockage can also decrease blood flow and cause deterioration to portions of the bowels, along with the absorption of toxic contents. Linear foreign objects like string, rope, and carpet fibers can also cause the intestines to bunch into each other like a telescope. These blockages may either be due secondary to ingesting foreign objects or materials. In some cases, however, especially with seniors, it may be a tumor or mass(1).

Most frequently, bowel obstructions are caused when a dog ingests foreign objects, such as toys, rocks, bones, and more. These objects are unable to pass through the intestines and become lodged. They can also cause perforation of the stomach and intestines.

Occasionally, other medical conditions can cause bowel obstruction in dogs. These include masses or tumors, twisting of the intestines around the membrane that separates them from the abdominal wall, pyloric stenosis (narrowing of the passage from the stomach to the small intestine), hernias, and intestinal parasites(8).

Along with the history, physical findings help direct the clinician regarding what specific tests, if any, should be done and how quickly a work-up should be expedited. Particular attention is paid to the animal's attitude, hydration, and posture. Abnormal posture (e.g. arched back) may indicate abdominal pain that can be associated with acute or chronic disorders. Bodyweight and overall physical stature should be noted. The act of defecation, especially if there is a history of dyschezia or tenesmus, should be observed by the clinician whenever possible(4).

Careful abdominal palpation is done to examine for thickened bowel (inflammatory or neoplastic infiltration), intussusception, presence of a mass that could be causing partial intestinal obstruction with resultant diarrhea, and lymphadenopathy (benign or neoplastic). The caudal dorsal abdominal region should be palpated in dogs with signs of large bowel diarrhea to see if there is evidence of discomfort. A rectal examination is always done in dogs with diarrhea, of any type, to examine for increased mucosal sensitivity, presence of narrowing (e.g. infiltrative disease, stricture), foreign body, or mass effect and to obtain a fresh stool sample for gross examination(2).

In the current report the animal show sign of edema especially of lower parts(legs) which indicated hypoproteinemia and confirmed by the low total protein value of the diseased dog.

It has been shown that a Protein-Losing Enteropathy (PLE) in Dogs could occur for different causes, Primary gastrointestinal disease, heart disease, and diseases of the lymphatic system can all cause PLE. When the body is functioning normally, plasma proteins that end up in the gastrointestinal tract are broken down

and reabsorbed by the body. When a disease entity occurs, protein loss may exceed protein manufacturing by the body. This is called (Hypoproteinemia) When hypoproteinemia is severe, fluid may leak from the circulation into the abdomen or out of the tiny blood vessels in the limbs, causing swelling of the legs(9). On the other hand, Marks, 2007 (10) added that Protein-losing enteropathy (PLE) is a syndrome caused by a variety of gastrointestinal diseases causing the enteric loss of albumin and globulin. Intestinal inflammation, infiltration, ulceration, blood loss, and primary or secondary lymphangiectasia are well-documented causes of PLE, If left untreated, the outcome of PLE is pan-hypoproteinemia with decreased intravascular oncotic pressure and the development of abdominal and pleural effusion, peripheral edema, and death. An important sequel to PLE includes thromboembolic disease secondary to the loss of antithrombin.

Results of the current reports were also indicated some electrolyte disorders, Since, Hypernatremia and Hyperkalemia were obvious in the diseased dog.

Disorders of sodium and potassium occur and occasionally need symptomatic therapy. Hypernatremia primarily indicates loss of free water, whereas hyponatremia may be attributable to various problems. It is important not to correct major aberrations of serum sodium concentrations too quickly lest the therapy is more detrimental than the electrolyte abnormality. In distinction, hypokalemia and hyperkalemia may be corrected quickly(11). On the other hand, Goldkamp, _and Schaer, 2007 (12) added that Hypernatremia could be life-threatening and is caused by imbalances in water and sodium that occur from either water loss or sodium gain, often in the presence of inadequate water intake. The resultant hyperosmolarity, if acute or severe, can result in rapid shifts of water from the intracellular to extracellular space, causing intracranial hemorrhage and neurologic changes. Correction of hypernatremia through inappropriate fluid therapy can result in even more severe complications, ranging from cerebral edema to coma and death.

Further, It has been documented that, Increased sodium and water resorption causes a dilutional effect, thus decreasing renal tubular potassium excretion. Causing hyperkalemia, Nevertheless, Hyperkalemia is expressed by markedly higher than normal concentrations of potassium in the blood. Normally eliminated in the kidneys, potassium and its increased acidity in the dog's blood can have a direct impact on the heart's ability to function normally, making this a high-priority condition. Elimination is enhanced by aldosterone, a hormone that causes the tubules of the kidneys to retain sodium and water. Therefore, conditions that can inhibit renal elimination of potassium can be a direct cause of hyperkalemia(13).

V. Management & Prevention

The best way to prevent bowel obstruction is to discourage and block the dog from trying to eat certain types of bones, sticks, rocks, and similar objects. Keep foods that are toxic to dogs and other temptations, including garbage cans, out of reach. Teaching the "Leave It" command can prevent the dog from attempting to explore something harmful. Only give the puppy or dog toys and treats that are safe and appropriate for them to chew. Call the veterinarian immediately if you suspect or know your dog ate something unusual(14).

Prognosis varies depending on the severity of the obstruction and the presence of complicating factors such as necrosis or peritonitis. Most pets recover fine. However, post-surgery, dogs must be monitored for any signs of leakage from the intestinal tract. Fever and abdominal pain should be reported to the vet immediately(3).

After surgery, the dog will have to gradually work its way back to solid foods. It should eat a liquid diet for the first few days. Then can gradually introduce mushy, soft food until the vet allows a normal diet. The dog may also need to wear an Elizabethan collar to prevent him from chewing on his stitches(4).

References

- [1]. Washabau, R. J. (2013). Large Intestine: Canine and Feline Gastroenterology. ELSEVIER :729–777.
- [2]. Tams ,T. R. (2001). Diagnosis and Management of Large Intestinal Disorders in Dogs.<https://www.vin.com/apputil/content/defaultadv1.aspx?id=3844072&pid=11131>.
- [3]. AKC Staff .(2020). Bowel Obstruction In Dogs: Symptoms, Treatment, and Prevention. <https://www.akc.org/expert-advice/health/bowel-obstruction-in-dogs/>.
- [4]. Beugnet, F., Halos,L., Guillot,J.(2018). Textbook of clinical parasitology in dogs and cats. ISBN: 978-2-9550805-2-8.
- [5]. Ettinger, S.J and Feldman, E.C (2005). Text book of Veterinary Internal Medicine: Disease of Dog and Cat (6th edn). In: WB Saunders (Ed.), Philadelphia, USA.
- [6]. Papazoglou, L. G., Patsikas, M. N., T. Rallis.(2003).Intestinal Foreign Bodies in Dogs and Cats. Compendium.15(11),830-844.
- [7]. HAYES, G.(2009). Gastrointestinal foreign bodies in dogs and cats: a retrospective study of 208 cases. Small Anim. Pract.50: 576–583.
- [8]. ARONSON, L. R., BROCKMAN, D. J. & BROWN, D. C. (2000) Gastrointestinal emergencies. Vet Clin North Am Small Anim Pract.. 30: 555-579.
- [9]. Neiger, Reto.(2013). Protein-Losing Enteropathy (PLE) in Dogs. <https://www.vin.com/apputil/content/defaultadv1.aspx?pid=11372&catId=35322&id=5709878>.
- [10]. Marks, S.L.(2007). Diagnosis and Management of Protein-losing Enteropathies.<https://www.vin.com/apputil/content/defaultadv1.aspx?id=3860867&pid=11242&print=1>.
- [11]. Willard, M.(2008). Therapeutic approach to chronic electrolyte disorders. Vet Clin North Am Small Anim Pract. 38(3):535-41.
- [12]. Goldkamp, C and Schaer, M. (2007). Hypernatremia in dogs. Compend Contin Educ. Vet. 29(3):148.

- [13]. Segev, G., Fascetti, A.J., Weeth, L.P., Cowgill, L.D. (2010). Correction of Hyperkalemia in Dogs with Chronic Kidney Disease Consuming Commercial Renal Therapeutic Diets by a Potassium-Reduced Home-Prepared Diet. *Vet.Inte.Med.* 24(3):546-550.
- [14]. CLARKE, N.(2008). TRAINING REX IN THE CITY BASIC OBEDIENCE FOR DOGS. Published by the City of Vancouver.

Kamal M.Al Saad, et. al. "Stenosis of the large intestine in a dog (A case report)." *IOSR Journal of Agriculture and Veterinary Science (IOSR-JAVS)*, 14(4), 2021, pp. 62-67.