

Spirometrosis in Asiatic Lion (*Panthera Leo persica*) at the National Zoo: trace back to epidemiological studies reveals the potential risk of human sparganosis in Bangladesh

Ahasan Syed Ali^{1*}, Azam SU², Mohanto K³, Rahman S⁴, Islam MT⁵,
Anisuzzaman⁴, KhanMAHNA¹, Begum NJ⁴, Chowdhury EH^{1*}

¹(Department of Pathology, Bangladesh Agricultural University, Bangladesh)

²(Department of Parasitology, Monash University, Australia)

³(Department of Medicine and Public Health, Sher-E-Bangla Agricultural University, Bangladesh)

⁴(Department of Parasitology, Bangladesh Agricultural University, Bangladesh)

⁵(Department of Medicine, Bangladesh Agricultural University, Bangladesh)

Abstract:

Background: Multiple host involvement and developmental stages of *Spirometra* cause multifaceted zoonotic health hazards. Canines and felines are definitive hosts, planktonic crustaceans of the genus *Cyclops* are first intermediate hosts, and fish, reptiles and amphibians are second intermediate hosts in the life cycle of *Spirometra*. Spargana, the infective larval stage, may infect other animals and humans. Despite the abundance of spirometrosis in most Asian countries surrounding Bangladesh, only a few sporadic parasitological reports are available in Bangladesh to date.

Materials and Methods: A study was undertaken for the clinical-parasitological and morphological assessment of Spirometrosis in an Asiatic lion (*Panthera Leo persica*) at Bangladesh National Zoo. Consequently, Traces back to epidemiological investigations on copepods (*Cyclops*), Asian bullfrogs (*Hoplobatrachustigerinus*), water snakes (*Tropidonotus* spp.) and buffalo meat (*Bubalus bubalis*) to detect larval stages were done to assess human risk of spargana infection in Bangladesh stemming from shared pastures (between human and other hosts) and meat from buffalo from those pastures on which the lion was used to feed on. Level of significance on disease prevalence among variables was done using Chi-square with Fisher's exact probability test.

Results: Spirometrosis in the Asiatic lion was indicated by the (i) presence of plenty of *Spirometra* eggs in faeces in absence of other much detrimental pathogens on coprology, (ii) pale visible mucous membrane followed by recumbence and death as characteristic clinical signs, (iii) declined hematopoietic function (Hb, 3.2mg/dl) as anemia on hematology, and (iv) splenic atrophy and pale but normal texture of all other visceral organs on necropsy and histopathology. Epidemiological studies demonstrated presence of numerous *Spirometra* eggs, coracidia and procercoids in and around *Cyclops* (39.33%) under the microscope. Frogs (27.5%) and water snakes (26.7%) represented pleurocercoid. Buffalo meat (13.3%) demonstrated pleurocercoids under the fibrous layer in the trace back study which is indicative to high risk of sparganosis (Human spirometrosis) in Bangladesh. Influence of variables on disease prevalence was statistically insignificant ($p > 0.05$).

Conclusion: The abundant stagnant water bodies of pastures shared by crustacean copepods, frogs, snakes, buffaloes and humans; habitual use of infected water bodies and availability of all developmental stages of *Spirometra* may suggest a potential risk of human sparganosis in Bangladesh.

Key Word: Spirometrosis, sparganosis, crustaceans, *Cyclops*, frogs, water snakes, buffalo meat, pleurocercoid, Bangladesh.

Date of Submission: 03-06-2020

Date of Acceptance: 18-06-2020

I. Introduction

Spirometra is a pseudophyllidean cestode of the family Diphyllbothriidae which is a globally distributed tapeworm infecting the intestines of canine and feline carnivores of zoos with domestic and wild predators as definitive hosts (1, 2, 3, 4). These carnivore hosts shed eggs through feces allowing diagnosis due to the typical characteristics of egg (5, 6). The first intermediate host is a planktonic crustacean copepod of the genus *Cyclops* which ingests coracidia that hatch from *Spirometra* eggs (7). In the tissues of the copepod, the coracidium develops into the first larva or procercoid (8). When a second intermediate host ingests an infected copepod, the procercoid develops into a second larval form, the pleurocercoid also known as sparganum (9, 10, 11, 12, 13, 14). Pleurocercoid infects many vertebrates including amphibians, reptiles, birds, small mammals,

non-human primates, and also humans (15, 16). Various mammals and bird species become infected by predating parasitized frogs or snakes (17,18). Contaminated water by feces from infected definitive hosts assures the cycle to be perpetuated (19).

Spirometra affects the host in many ways like pernicious anemia and enteritis (20) and pathogenesis is not well known in animals (21, 22, 23). Mechanical blockage may cause twisting of intestines (24) and toxicity that may result in digestive disturbances, diarrhea, stunting of growth, emaciation, edema and anemia (25). Death may result from cumulative effects of the tapeworms even after a long convalescence or suddenly from acute toxemia (26). Additionally, obstructive jaundice may result by blocking bile ducts (27).

Sparganosis has recently been highlighted as an emerging and re-emerging food-borne zoonosis in reptiles, amphibians and humans (28, 29, 30). The spargana, varying between 4 and 10 cm in length, is found in a variety of tissues of the secondary intermediate hosts and paratenic hosts through larval transfer (31). Humans can be infected by proceroids through drinking freshwater contaminated by infected crustaceans and by spargana through eating raw or undercooked infected foods (32, 33, 34, 35, 36), the latter being traditionally linked to dietary customs or risk behaviors (37).

Spirometrosis and sparganosis are increasingly reported from almost all Asian countries such as Japan (38), China (39, 40, 41), Korea (42), Thailand (43, 44), Cambodia (45) and India (46, 47). Among them, Korea appears to have reported a higher number of human sparganosis cases.

Bangladesh is sporadically reported with diphyllbothriasis(48, 49) and spirometrosis(50, 51, 52) along with another thirty recorded zoonotic parasites (53, 54). But a holistic approach combining clinical and histopathological interventions to identify spirometrosis with tracking of previous epidemiological studies to identify proceroid and pleuroceroid larval stages of spargana has not yet been addressed in Bangladesh. The presence of abundant stagnant and shared water bodies for *Cyclops*, frogs, water snakes, buffaloes and fishes combined with high risk behaviors including health management and husbandry practices in Bangladesh which is highly conducive for easy transmission of *Spirometra* along with other parasites. Considering the above facts, the present study was designed to assess three aspects objectively, including (i) clinical-parasitological and histopathological diagnosis of *Spirometra* in Asiatic lions (*Panthera Leo persica*) at Bangladesh National Zoo, (ii) trace back to epidemiological investigations of proceroid and pleuroceroid stages (spargana), and (iii) analyze the potential risk of human sparganosis in Bangladesh.

II. Material and Methods

Investigation of lion

Fecal samples of four out of five Asiatic lions (*Panthera Leo persica*) of different ages from enclosure No. C-22 (Popularly known as Lion Moat) of the National Zoo were collected and fixed with 10% neutral buffered formalin. Parasitological examination was done simultaneously in the laboratory of the Department of Parasitology, Bangladesh Agricultural University (BAU) and Central Disease Investigation Laboratory (CDIL) using simple flotation and sedimentation techniques.

Whole blood samples from a critically ill male lion of 6 years of age were subjected to hematological investigation. Physical tests of consistency, eye estimation of color match and acid hematin method for measuring Hb concentration were done in the clinical laboratory of Bangladesh Agricultural University, Mymensingh (BAU).

After death of the critically ill lion, necropsy, all vital organs were examined for gross lesions and parts of the tissue (liver, lung, kidney, spleen, testes, heart, urinary bladder, tongue and penis) were fixed in 10% neutral buffered formalin immediately. Histopathology was done by routine hematoxylin and eosin staining (Luna)(55) in the Department of Pathology, BAU. Inclusion of buffalo meat as basic ration was suspected for lion population to be infected by *Spirometra* followed by an epidemiological study.

Trace back epidemiology

Stagnant water of 3 to 4.5 feet depth from shared habitat and specimens of water snakes (*Tropidonotus spp.*), bullfrogs (*Hoplobatrachustigerinus*) and suspected buffalo meat (*Bubalus bubalis*) from Nandina, Jamalpur and Bhaluka, Mymensingh were collected, particularly in the dominant seasons e.g., summer (March-June) and rainy season (August-October). Parasitological examination was done in the Department of Parasitology and histopathology in the Department of Pathology of BAU. Parasitological and histopathological tests were done according to the descriptions given by Soulsby (56), Hendrix and Robinson (57) and Bowman and Lynn(58); and Luna (59) respectively.

Chi-square with Fisher's exact probability test was done to find out the significant differences in the occurrences of proceroids and pleuroceroids between seasons and study areas.

Cyclops (n=600) were studied under the microscope (X10, X40, X60) for proceroids; frogs (n=40) and water snakes (n=15) were studied by dissection and gross inspection of subcutaneous tissue for pleuroceroids; buffalo

meat (n=30) (meat that used as lion ration) correlating with shared pastures were inspected visually and histopathologically for pleurocercoids.

Photomicrographs of *Cyclops* with procercooids, buffalo meat with pleurocercoids and histopathology were taken using a photomicrographic camera (Olympus PM-C 35 Model) and a digital camera-mounted photomicrographic device (Differential Interference Contrast – DIC) (Olympus, Nizol FC, E-5000, 8.4V, 0.9A, CE N 150) at the Department of Pathology and Field Fertility Clinic of the Department of Surgery and Obstetrics, BAU.

The whole extensive experiment took a longer period of time through 2008 to 2018 in order to complete trace back study.

III. Result

Findings from study on lion

One male lion (Fig. 1) of 6 years of age at Dhaka Zoo clinically represented gradual anorexia, extreme emaciation, pale conjunctiva, reluctance and staggering gait, on-drowsiness, dribbling of urine, hind quarter paralysis, loss of physical color and viscosity of blood, non-responsive to medication, complete cessation of urination and defecation followed by recumbence and death.

Findings of characteristic eggs (Fig. 2) in lion feces revealed that one out of the four lions were suffering from infection by *Spirometra*(Table 1).

Visual examination of blood from *Spirometra*-infected lion showed thin and pale. Hematology (acid hematin method) revealed a lower level of hemoglobin concentration (Hb%, 3.2 mg/dl; normal value 12-14 mg/dl) suggesting a situation of declined hematopoietic function and anemia.

Necropsy demonstrated a high degree of paleness of organs examined (Fig. 3 A-C and Fig. 4 A-F). The study of histopathology depicted seriously anemic internal organs with normal architecture (Fig. 5 A-H) except splenic atrophy (Fig. 6).

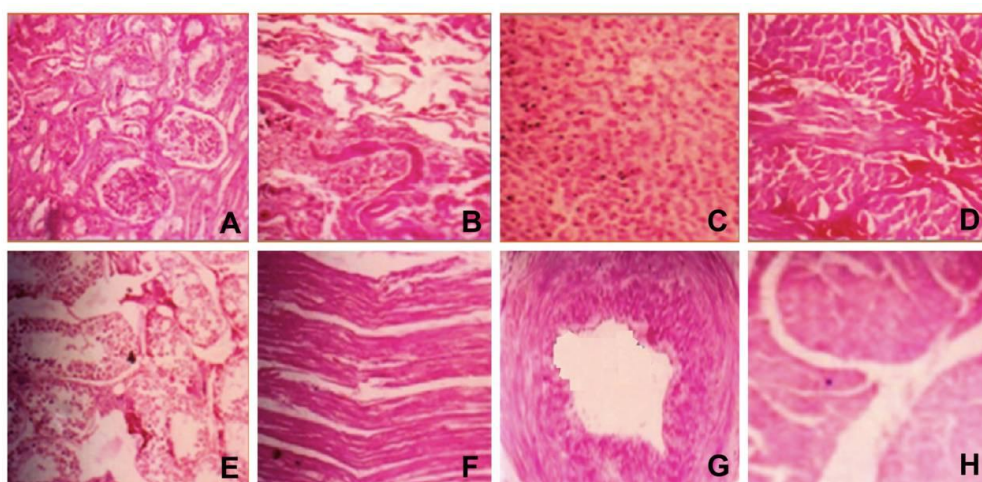
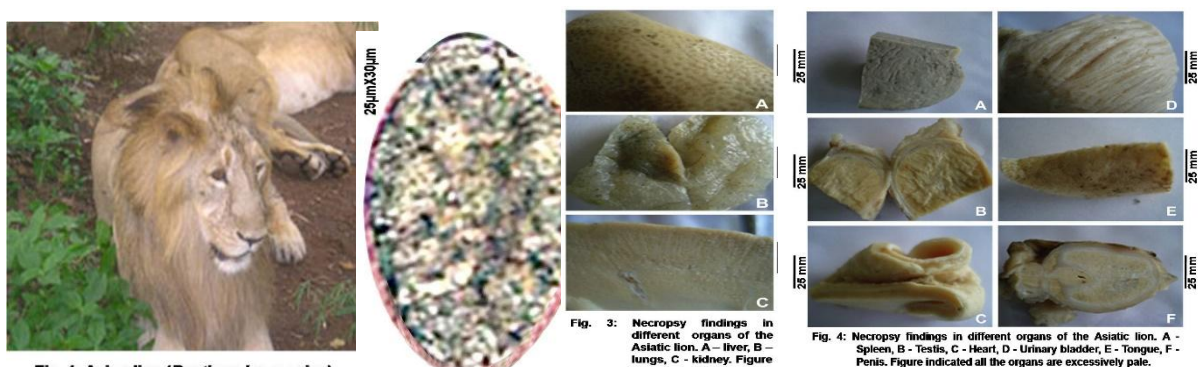


Figure 5: Histopathology by staining of all vital organs of the Asiatic lion. A-kidney B-lung C-liver D-tongue E-testis F-heart G-penis H-urinary bladder. Organs anemic but architecturally normal, H&E, x82.5.

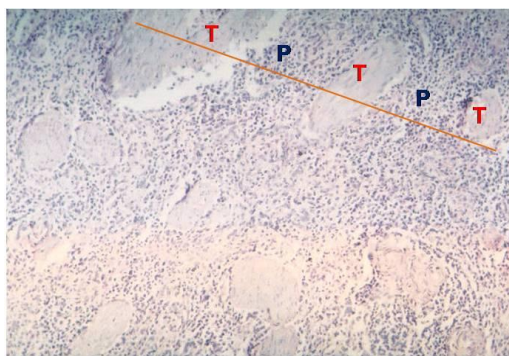


Fig. 6: Spleen of Asiatic lion, prominent and huge number of trabeculae (T) in a single focus; and shrinkage of parenchyma (P) seen through the line,

Prevalence of proceroids in crustacean copepods (*Cyclops*, 1st intermediate hosts of *Spirometra*) and pleuroceroids in amphibians (2nd intermediate hosts of *Spirometra*) in different geographic areas and dominant seasons:

Prevalence of proceroids in *Cyclops* (N=600) examined from Nandina (n=400) were 40% and from Bhaluka (n=200) were 38% (Table 2). Proceroids were found mostly in the haemocoel and some in oesophageal tube of *Cyclops* (Fig. 7, Bc). *Spirometra* eggs (Fig. 7, Ba) were found outside; and coracidia (Fig. 7, Bb) and proceroid were found inside of most of the *Cyclops* examined (Fig. 7, Bc). Proceroid infested *Cyclops* was prevalent at the rate of 40% in the rainy season and 37.33% in the summer season being overall prevalence rate was 39.3% (Table 2). However, present study revealed statistically insignificant ($p > 0.05$) geographical ($p = 0.636$) and seasonal ($p = 0.563$) influence on the prevalence of proceroids of *Spirometra* (Table 2).

Examination of the subcutaneous tissues of frogs (*Hoplobatrachustigerinus*) (n=40) and water snakes (*Tropidonotus* spp.) (n=15) revealed the presence of pleuroceroid of *Spirometra* (Fig. 8). Pleuroceroids were found flattened and attached with muscle of gluteus and intercostals in fresh buffalo meat (*Bubalus bubalis*) (n=30) (Fig. 9 and 10).

Overall prevalence of pleuroceroids was 27.5% in frogs, 26.7% in water snakes and 13.3% in buffaloes (Table 3). Present study demonstrated statistically insignificant ($p > 0.05$) geographical and seasonal influence on prevalence of pleuroceroids also (Table 3). However, stagnant water bodies used in this study had a history of sharing by buffaloes, frogs, water snakes, fishes and even humans.

Prevalence of pleuroceroid-infected frog was 28.00% in summer and 26.7% in rainy season (Table 3). Prevalence of infected frogs was 30.00% in Nandina, Jamalpur and 25.00% in Bhaluka, Mymensingh (Table 3). In case of water snakes, prevalence was 30% in rainy and 20% in summer season; and it was 33.3% in Nandina, Jamalpur and 16.7% in Bhaluka, Mymensingh (Table 3). Prevalence was 14.3% in rainy and 13.0% in summer season, 13.6% in Nandina, Jamalpur and 12.5% in Bhaluka, Mymensingh in case of buffalo (Table 3).

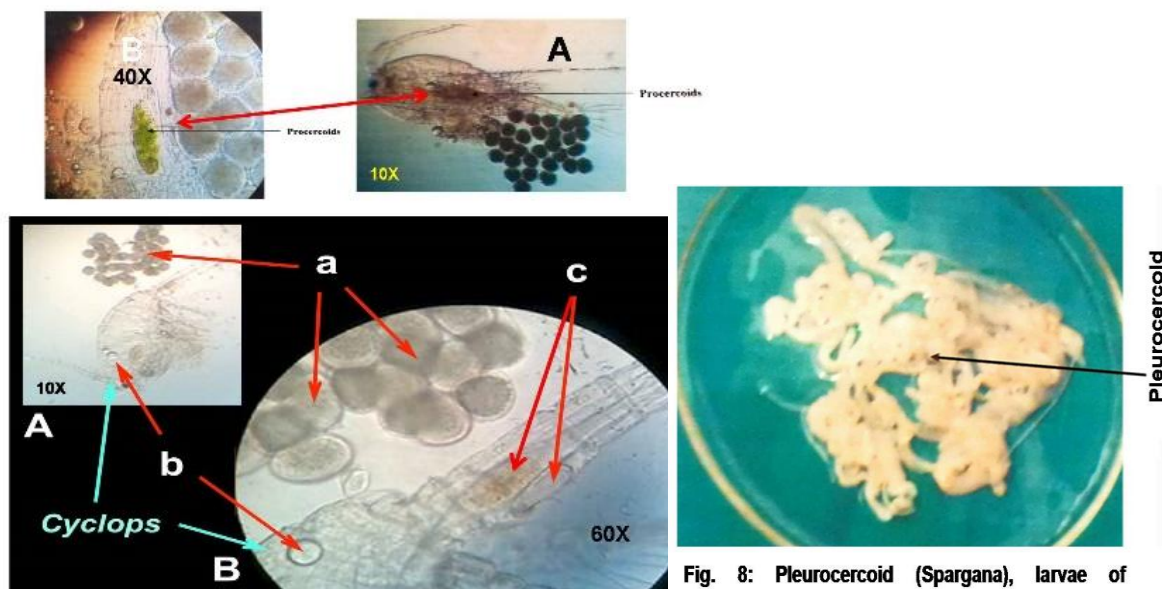


Fig. 8: Pleuroceroid (Spargana), larvae of

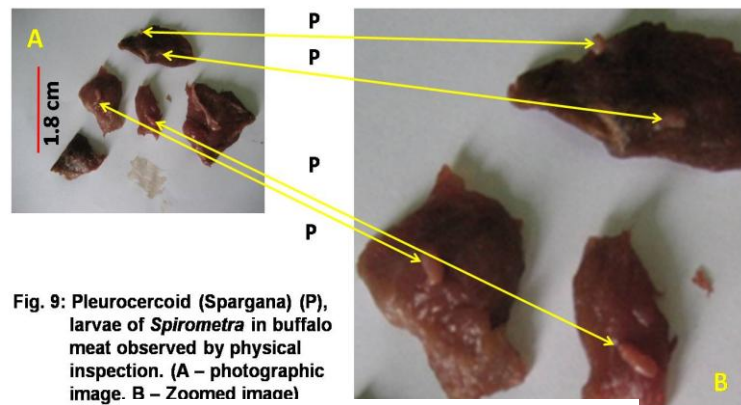


Fig. 9: Pleuroceroid (Spargana) (P), larvae of *Spirometra* in buffalo meat observed by physical inspection. (A – photographic image. B – Zoomed image)

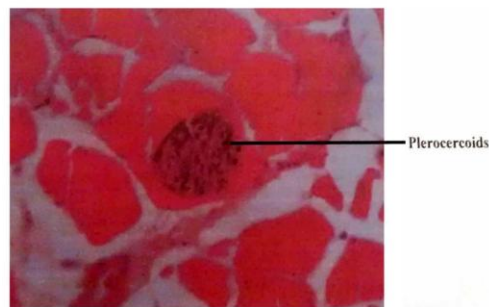


Fig. 10: Pleuroceroid (Spargana), larvae of *Spirometra* in gluteus muscle of Asiatic lion

Table 1: Parasitological findings. Eggs of *Spirometra* present in feces of one Asiatic male lion (*Panthera leopercica*)

Sl. No.	English name, Enclosure no., Given name, Sex, Age *	Parasitology lab, BAU	Lab, endoparasitic division, CDIL
1	Asiatic Lion; (C-22), Moat (East); Bangale; ♂; 12Y 5 M	<i>Toxocara</i>	<i>Troglotrema, Toxocara</i>
2	Asiatic Lion; (C-22), Moat (West); Diptee; ♀; 13 Y	No ova found	<i>Strongyles</i> ⁺⁺
3	Asiatic Lion; (C-22), Moat (Middle); Rafel; ♂; 6 Y	<i>Toxocara</i>	<i>Troglotrema</i> ⁺⁺⁺ , <i>Ascaris</i> ⁺⁺
4	Asiatic Lion; (C-22), Moat (Middle); Ringo/Birbal; ♂; 6 Y	<i>Spirometraspp.</i> ⁺⁺⁺	<i>Spirometraspp.</i> ⁺⁺⁺ , <i>Stongyles</i> ⁺⁺

*♂=Male, ♀=Female, Y=Year, M=Month; BAU=Bangladesh Agricultural University, Mymensingh; CDIL=Central Disease Investigation Laboratory of Department of Livestock Services, Bangladesh.

Table 2: Area- and season-wise prevalence of proceroids in Cyclops

Variables	Nos. of Cyclops Examined	Cyclops affected		P-value
		Nos.	Percentage	
Study area				
Nandina, Jamalpur	400	160	40.0	0.636
Bhaluka, Mymensingh	200	76	38.0	
Season				
Summer (March - June)	150	56	37.3	0.563
Rainy (July - October)	450	180	40.0	
Total	600	236	39.3	

Statistically insignificant ($p>0.05$) geographical ($p=0.636$) and seasonal ($p=0.563$) influence

Table 3: Area- and season-wise prevalence of pleuroceroids in frogs, water snakes and buffaloes

Variables	Frogs			Water snakes			Buffaloes		
	Nos. examined	Nos. affected	%	Nos. examined	Nos. affected	%	Nos. examined	Nos. affected	%
Study area									
Nandina	20	6	30.0 ^a	9	3	33.3 ^a	22	3	13.6 ^a
Bhaluka	20	5	25.0 ^a	6	1	16.7 ^a	8	1	12.5 ^a
Season									
Summer	25	7	28.0 ^a	5	1	20.0 ^a	23	3	13.0 ^a
Rainy	15	4	26.7 ^a	10	3	30.0 ^a	7	1	14.3 ^a
Total	40	11	27.5	15	4	26.7	30	4	13.3

Percentage bearing same superscript letter within a column did not differ significantly ($p>0.05$).

IV. Discussion

Coprolological identification of spirometrosis in this study is consistent with previous other findings (60, 61, 62, 63, 64). But this is the first confirmation of clinical (thin and pale blood, Hb concentration 3.2 mg/dl against normal value, 12 mg/dl) and histopathological (anemic internal organs) evidence of spirometrosis in Bangladesh. All the clinical signs of *Spirometra* infection in lion were also carefully noted for the first time in Bangladesh. The results of the present study suggested high infection intensity in the large cats of the National Zoo as same buffalo meat is being supplied to all large cats there in (65). Similarly, in an investigation of multi-parasitism in dog, prevalence of *Spirometra* was 21.3% in Cambodia (66). Spirometrosis was described in a cat experimentally fed raw fish from India (67).

Investigation of proceroids in *Cyclops* in Bangladesh has not been reported before this study. There are numerous reports on investigation of coracidia in *Cyclops* but this study showing clusters of eggs, coracidia and proceroids in a single focus in and around copepods is unique and different from all other reports ever made to be known, globally. However, proceroids in *Cyclops* were mentioned by Soulsby (68) and Bowman and Lynn (69) in their books as extensively reported from different countries.

Both the intermediate hosts (*Cyclops* and amphibians) were found vulnerable to larval infection in rainy over summer season and hosts of Nandina, Jamalpur were more infected than those of Bhaluka, Mymensingh, although these differences were statistically insignificant ($p>0.05$). However, these findings were not compared due to data deficiency.

Sparganosis in second intermediate hosts are frequently reported in a variety of vertebrates including birds, snakes and humans (70); native fowls, water snakes, frogs, pythons and mongoose (71) but comprehensive epidemiological research looking at retrospective studies on sparganosis (72) like ours has not been reported to date. Our findings of spargana in amphibians can be compared with the findings by Veena and Imkongwapangin Nagaland (73), Bengston and Rogersin USA (74) and by Park and associates (75), Lin and associates (76) and Lai and associates (77) in Korean Peninsula. Findings of spargana in reptiles e.g. snakes as recorded, in this study, also conform to the report by Bengston and Rogers (78), Kim and associates (79), Lin and associates (80), Yang (81), Lai and associates (82) and Tung and associates (83). Sparganosis has been reported by several authors like Bengston and Rogers (84) in swine in USA, by Yang (85) in mice in China, in dogs by Naveen and associates (86) in India, in birds by Tung and associates(87) in Taiwan and by Nobrega and associates(88) in baboons in Tanzania. But no reports or records are available as to its occurrence in buffaloes. As such, recording of sparganosis in buffaloes in this study is presumed to be unique work till date, globally.

Finding of sparganosis in humans in different countries such as in Taiwan (89), France (90, 91); USA (92), Japan (93). Thailand (94, 95) and Korean peninsula (96, 97, 98, 99, 100); and I European countries (101, 102, 103) were correlated with the practice of eating improperly cooked or raw snakes and frogs. These findings

can be compared with the prevalence of *Diphyllobothrium latum* and *Spirometramansonif* from dog and cats in Bangladesh (104). This establishes the fact that the presence of these tapeworms also signifies and supports *Cyclops* being infested by proceroids in this country. Therefore, it is likely that buffaloes with the habit of swallowing stagnant water might swallow *Cyclops* infested with proceroids, consequently leading to development of spargana in muscular tissues.

The human food chain that includes infected drinking water is known to play a crucial role in almost all the human sparganosis cases reported to date (105). Given that buffalo is a popular source for animal protein, local traditions of eating undercooked meat represent a risk of human infection emergence in Bangladesh. Hence, forecasting for human sparganosis in Bangladesh could be apprehended according to risk behaviors already emphasized (106).

Other than humans, there are reports of paratenic host from Poland where no adult *Spirometra* were noticed from the intestine of a badger but spargana was found in several subcutaneous spots (107).

It is worth mentioning, given that among infections by platyhelminthes, cestodiasis have not been noted to be emerging as a consequence of climate change and/or anthropogenic modifications of the environment (108), as opposed to trematodiasis such as fascioliasis (109, 110, 111), zoonotic schistosomiasis and cercarial dermatitis (112, 113), all of them priorities in the agenda of the World Health Organization (114). In this study, we found stagnant water as a main harbor of *Spirometra*. It is apprehended that water logging and stagnation will increase resulting wide spread spirometrosis and sparganosis in Bangladesh as a negative impact of climate change.

V. Conclusion

Prevalence of proceroids in *Cyclops* and detection of spargana in buffalo muscle is reported for the first time in Bangladesh. Epidemiological study of spargana was reported in frogs, water snakes, and water buffaloes for the first time also. Further intensive studies are needed to determine other linkage (if any) with adult pseudophyllidean tapeworms with proceroid in *Cyclops* and sparganosis in different amphibians, reptiles, birds and mammals.

Research on zoonotic pathogens in wildlife should be prioritized, whenever possible by means of multidisciplinary one world-one health approaches including human and veterinary medical studies at the wildlife-livestock-human interfaces to prevent potentially emerging and re-emerging diseases. Efforts should be laid to keep people away from risk behaviors like drinking contaminated water and eating undercooked meat from any suspected sources. It should be of highly emphasized because of the zoonotic importance of the pseudophyllidean tapeworms.

Acknowledgements

Authors are indebted to the late Prof. M. Hafezur Rahaman for his untiring inspiration. We would like to extend our heartfelt thanks and gratitude to Dr. Karin Schwartz from USA for her exhaustive editing over the manuscript. Experts from CDIL and Bangladesh National Zoo, Department of Livestock Services, Bangladesh are acknowledged for their outfit supports and cooperation too.

Author Disclosure Statement

No competing financial interests exist.

References

- [1]. Naveen K, Aithal HP, Gupta SC. Sparganosis in dog: a rare case report. *Veterinary Practitioner*. 2004; 5(1): 55-56.
- [2]. Tung CC, Lin JW, Chou FF. Sparganosis in male breast. *Journal of the Formosan Medical Association*. 2005; 104(2): 127-128.
- [3]. Hendrix MC and Robinson Ed. *Diagnostic Parasitology for Veterinary Technicians*. Third Edition. Mosby in company. Elsevier Inc. Missouri. 2006; pp. 99-100.
- [4]. Nobrega LM, Hubbard G, Loverde P, Siler KT, Schlabritz LN. Sparganosis in wild-caught baboons (*Papio cynocephalus anubis*). *Journal Medicinal Primatol*. 2007; 36(1): 47-54.
- [5]. Rahaman MH, Ahamed S, Mondal MMH. *Introduction to Parasites of Animals and Birds in Bangladesh*, 1st edition, 1996; pp. 1-2.
- [6]. Ugarte CE, Thomas DG, Gasser RB, Hu M, Scott I, Collett MG. *Spirometra erinacei* / *S. erinacei europaei* in a feral cat in Manawatu with chronic intermittent diarrhea. *New Zealand Veterinary Journal*. 2005; 53(5):347-351.
- [7]. Soulsby EJJ. *Helminths, Arthropods and Protozoa of Domesticated Animal*. 7th edition, Bailliere Tindal, London. 1982; pp. 131-132.
- [8]. Bowman DD and Lynn RC. *Parasitology for Veterinarians*. 7th edition. W. B. Saunders Company, A Harcourt Health Sciences Company, The Curtis Center, Independence Square, West Philadelphia, PA 1999; pp. 127.
- [9]. Bengston SD and Rogers F. Prevalence of sparganosis by county of origin in Florida feral swine. *Veterinary Parasitology*. 2001; 97(3):239-42.
- [10]. Gillespie SH. Cutaneous larva migrans. *Current Infectious Disease Reports*. 2004; 6(1): 50-53.
- [11]. Iwatani K, Kubota I, Hirotsu Y, Wakimoto J, Yoshioka M, Mori T, Ito T, Nomori H. Sparganumansonii parasitic infection in the lung showing a nodule. *Pathol Int*. 2006; 56(11): 674-677.
- [12]. Walker P, Cooper NK, Brandis A. Cerebral sparganosis presenting as grand mal epilepsy. *Journal of Royal Army Medicinal Corps*. 2007; 153(3):189-190.

- [13]. Kim SH, Park S, Paik JH. Scrotal sparganosis: with an emphasis on ultrasonographic findings. *Urology* 2008; 71(2): 351.
- [14]. Qiu MH, Qiu MD. Human plerocercoidosis and sparganosis: I. A historical review on aetiology. *Chinese Journal of Parasitology and Parasitic Diseases*. 2009; 27(1):54-60.
- [15]. Choi SJ, Park SH, Kim MJ, Jung M, Ko BH. Sparganosis of the breast and lower extremities: sonographic appearance. *Journal of Clinical Ultrasound*. 2014; 42:436-438.
- [16]. Wang F, Li W, Hua L, Gong S, Xiao J, Hou F, Ge Y, Yang G. *Spirometra* (Pseudophyllidea, Diphyllbothriidae) severely infecting wild-caught snakes from food markets in Guangzhou and Shenzhen, Guangdong, China: implications for public health. *Scientific World Journal* 2014. Article ID 874014, 5 pages
- [17]. Park HY, Lee SU, Kim SH, Lee PC, Huh S, Yang YS, Kong Y. Epidemiological significance of sero-positive inhabitants against sparganum in Kangwon-do, Korea. *Yonsei Medical Journal*. 2001; 42(4): 371- 374.
- [18]. Lai CH, Kuo YC, Tung KC, Wang JS. A survey of endoparasitic infections of snakes in Taiwan. *Taiwan Veterinary Journal*. 2004; 30(1); 26-32.
- [19]. Lee KJ, Bae YT, Kim DH, Deung YK, Ryang YS. A seroepidemiologic survey for human sparganosis in Gangweon-do. *Korean Journal of Parasitology*. 2002; 40(4): 177-180.
- [20]. Chatterjee KD. Parasitology, Protozoology and Helminthology, 12th Edition, Chatterjee Medical Publishers. 1981; pp.111-97.
- [21]. Kolodziej-Sobocinska M, Tokarska M, Kowalczyk R. The first report of sparganosis (*Spirometra* sp.) in Eurasian badger (*Melesmeles*). *Parasitology International*. 2014; 63:397-399.
- [22]. Lucy S, Bindu L, K. Devada, P. Sundaresh Kumar. Occurrence of human sparganosis in Kerala. *Journal of Parasitic Diseases (JPD)*. 2014.
- [23]. Wiwanitkit V. Multiple sparganosis. *Arch Plast Surg (Archives of Plastic Surgery, APS)* 2014; 41(2):181.
- [24]. Wiwanitkit V. A review of human sparganosis in Thailand. *International Journal of Infectious Diseases*. 2005; 9:312-316.
- [25]. Soifer F and Bernstein J. Hematology of some zoo animals and exotic pets, In Krik, R.W. (ed.). *Current veterinary therapy V*. Philadelphia, W.B. Saunders, 1974.
- [26]. Sastry G A. *Veterinary pathology* 6th edition, CBS Publication India 1998; pp. 722-723.
- [27]. Boonyasiri A, Cheunsuchon P, Suputtamongkol Y, Yamasaki H, Sanpool O, Maleewong W, Intapan PM. Nine human sparganosis cases in Thailand with molecular identification of causative parasite species. *The American Journal of Tropical Medicine and Hygiene*. 2014; 91(2):389-93.
- [28]. Lee YI, Seo M, Park HW. Recurred sparganosis one year after surgical removal of a sparganum in a Korean woman. *The Korean Journal of Parasitology*. 2014; 52(1):75-78.
- [29]. Nelson GS, Pester FRN, Rickman R. The significance of wild animals in the transmission of cestodes of medical importance of Kenya. *Transactions of the Royal Society of Tropical Medicine and Hygiene*. 1965; 59(6): 507-524.
- [30]. Norman SH, Kreutner A Jr. Sparganosis: clinical and pathologic observations in ten cases. *Southern Medical Journal*. 1980; 73(3):297-300.
- [31]. Khalil F. Zoonotic helminths of wild and domestic animals in Africa. In: *Parasitic Helminths and Zoonoses in Africa* (ed. Macpherson, C. N. L. & Craig, P. S.), Unwin Hyman, London. 1991; pp. 260-272.
- [32]. Walker MD and Zunt ZR. Neuroparasitic Infections: cestodes, trematodes, and protozoans. *Seminars in Neurology*. 2005; 25(3): 262-277.
- [33]. Li M-W, Lin H-Y, Xie W-T, Gao M-J, Huang Z-W, Wu J-P, Li C, Lin R-Q, Zhu X-Q. Enzootic sparganosis in Guangdong, People's Republic of China. *Emerging Infectious Diseases*. 2009; 15(8): 1317-1318.
- [34]. Magnino S, Colin P, Dei-Cas E, Madsen M, McLauchlin J, Nöckler K, Maradona MP, Tsigarida E, Vanopdenbosch E, Peteghem CV. Biological risks associated with consumption of reptile products. *International Journal of Food Microbiology*. 2009; 134:163 – 175.
- [35]. Yamane Y, Okada N, Takihara M. On a case of long term migration of *Spirometraerinacei* larva in the breast of a woman. *Yonago Acta Medica*. 1975; 19(3):207-213.
- [36]. Lui YX, Xu XZ, Tong DS, Tang F. *Spirometramansoni* infection in an infant: one case report. *Chinese Journal of Schistosomiasis Control*. 2013; 25(2):221.
- [37]. SchärF, Inpankaew T, Traub RJ, Khieu V, Dalsgaard A, Chimnoi C, Sok D, Marti H, Muth S, Odermatt P. The prevalence and diversity of intestinal parasitic infections in humans and domestic animals in a rural Cambodian village. *Parasitology International*. 2014; 63(4):597-603.
- [38]. Sen DK, Muller R, Gupta VP, Chilana JS. Cestode larva (sparganum) in the anterior chamber of the eye. *Tropical and Geographical Medicine*. 1989; 41(3):270-273.
- [39]. Uddin M, Dewan ML, Huq MM. Occurrence of *Diphyllbothrium latum* in chicken and common Myna. *Bang Vet J*. 1979; 13(1-2):55-57.
- [40]. Uddin M, Dewan ML, Hossain MI, haq MM. Occurrence of *Diphyllbothrium latum* larvae in Lotya fish. *Bang Vet J*. 1980; 14(4): 33.
- [41]. Samad MA and Rahman MH. Investigation of endoparasitic infections in stray cats in Bangladesh. *Bangladesh Veterinary Journal*. 1998; 32(3-4): 142 - 150.
- [42]. Mamun MAA, Azam SU, Islam MN, Bari T, Khatun MM. Incidence of intestinal helminths in Asiatic lions (*Panthera leopersica*) at Dhaka Zoo, Bangladesh. *ZOO's PRINT*. 2014; 29 (11): 22-25.
- [43]. Raja MMRU, Dey AR, Begum N, Kundu UK, Ashad FA. Coprological prevalence of gastrointestinal parasites in carnivores and small mammals at Dhaka Zoo, Bangladesh. *Journal of Threatened Taxa*. 2014; 6(3): 5574-5579.
- [44]. Rahman MH. Incidence of some helminth parasites of zoonotic significance in street - dogs in some districts of Bangladesh. *Bangladesh Veterinary Journal*. 1973; 7(1-4), 14-16.
- [45]. Luna LG. *Manual of Histologic Staining Methods of the Armed Forces Institute of Pathology* 3rd Edition. Mc Graw Hill Book CO. New York 1968.
- [46]. Müller-Graf CDM. A coprological survey of intestinal parasites of wild lions (*Panthera leo*) in the Serengeti and the Ngorongoro Crater, Tanzania, East Africa, *Journal of Parasitology*. 1995; 81(5): 812-814.
- [47]. Müller-Graf CDM, Woolhouse MEJ, Packer C. Epidemiology of an intestinal parasite (*Spirometra* spp.) in two populations of African lions (*Panthera leo*). *Parasitology*. 1999; 118(4):407-415.
- [48]. Saleque A, Juyal PD, Bhatia BB. *Spirometra* sp. in a domestic cat in India. *Veterinary Parasitology* 1990; 35(3):273-276.
- [49]. Tang HJ. Epidemiological significance of water inhabitants against 1 sparganum in Kangwon-do, Korea. *Ozaki Medical Journal* .2005; 40(7): 371- 374.
- [50]. Rahman MH. Personal Communication. 2005.

- [51]. Mo ZS, Li XH, Lei ZY, Xie DY. Clinical analysis of twentyfive sparganosis cases. Chinese Journal of Parasitology and Parasitic Diseases. 2013; 31(3):218-20. (Article in Chinese).
- [52]. Veena T and Imkongwapang R. Natural infection of sparganum in frogs in Nagaland (northeast India)-an amphibia-borne zoonosis. Zoonosis Printjournal. 1999; 14(5): 13-16.
- [53]. Lin JX, Zhu K, Chen BJ. Sparganosis caused by frog flesh used for external application. Journal of Tropical Medicine Guangzhou 2002; 2(2): 167-168.
- [54]. Kim SH, Park K, Lee ES. Three cases of cutaneous sparganosis. International Journal of Dermatology. 2001; 40(10): 656-658.
- [55]. Yang HJ. Comparison of carbohydrate moieties of sparganum proteins of the snake, mouse and those of adult women. Korean Journal of Parasitology. 2003; 41(2): 135-137.
- [56]. Chang JHM, Lin OS, Yeh KT. Subcutaneous sparganosis – a case report and a review of human sparganosis in Taiwan. Kaohsiung Journal of Medical Sciences. 1999; 15(9): 567-571.
- [57]. Mougeot G, Cambon M, Menerath JM, Dimeglio V, Houin R. Human eye anterior chamber sparganosis. Parasite. 1999; 6(4): 365-366.
- [58]. Bottere F and Bouree P. Ocular sparganosis: a case report. Journal of Travel Medicine. 2003; 10(4): 245-246.
- [59]. Cummings TJ, Madden JF, Gray L, Friedman AH, McLendon RE. Parasitic lesion of the insula suggesting cerebral sparganosis: case report. Neuroradiology. 2000; 42(3): 206-208.
- [60]. Ishii H, Mukae H, Inoue Y, Kadota J, Kohno S, Uchiyama F, Nawa Y. A rare case of eosinophilic pleuritis due to sparganosis. Internal Medicine Tokyo. 2001; 40(8): 783-785.
- [61]. Imaroon A, Sukontason K, Sukontason K. Sparganosis: a rare case of the oral cavity. Journal of Oral Pathology and Medicine. 2002; 31(9): 558-560.
- [62]. Cho JH, Lee KB, Yong TS, Kim BS, Lee SY, Suh JS. Subcutaneous and musculoskeletal sparganosis: imaging characteristics and pathologic correlation. Skeletal Radiology. 2000; 29(7): 402-408.
- [63]. Kim JR and Lee JM. A case of intramuscular sparganosis in the sartorius muscle. Journal of Korean Medical Science. 2000; 16(3): 378-380.
- [64]. Pampiglione S, Fioravanti ML, Rivasi F. Human sparganosis in Italy: case report and review of the European cases. APMIS, Acta Pathologica, Microbiologica-et-Immunologica Scandinavica. 2003; 111(2): 349-354.
- [65]. Mas-Coma S, Valero MA, Bargues MD. Effects of climate change on animal and zoonotic helminthiasis. Revue Scientifique et Technique de l'Office International des Epizooties. 2008; 27(2): 443-457.
- [66]. Mas-Coma S, Valero MA, Bargues MD. Climate change effects on trematodiasis, with emphasis on zoonotic fascioliasis and schistosomiasis. Veterinary Parasitology. 2009a; 163 (4): 264-280.
- [67]. Mas-Coma S, Valero MA, Bargues MD. Fasciola, lymnaeids and human fascioliasis, with a global overview on disease transmission, epidemiology, evolutionary genetics, molecular epidemiology and control. Advances in Parasitology. 2009b; 69: 41-146.
- [68]. Afshan K, Fortes-Lima CA, Artigas P, Valero MA, Qayyum M, Mas-Coma S. Impact of climate change and man made irrigation systems on the transmission risk, long-term trend and seasonality of human and animal fascioliasis in Pakistan. Geospatial Health. 2014; 8: 317-334.
- [69]. Mas-Coma S, Bargues MD, Valero MA. Diagnosis of human fascioliasis by stool and blood techniques: Update for the present global scenario. Parasitology. 2014; 141 (Special Issue): 1918-1946.
- [70]. World Health Organization (WHO). Sustaining the drive to overcome the global impact of neglected tropical diseases. World Health Organization, WHO Headquarters, Geneva, 2013, pp.138.

