

## A Clinical Case of Panniculitis in a Cat (Case Report)

KAMAL M. AL-SAASD

Department of Internal & Preventive Medicine, College of Veterinary Medicine, University of Basrah, Iraq.

---

**Abstract:** A six months local cat breed, with a history of anorexia, fever, depression, and multiple clear subcutaneous nodules on the shoulder area located at both sides was presented to the consultant veterinary clinic. Complete clinical examinations have been applied to the diseased cat and a clinical diagnosis of panniculitis was suspected. Blood mixed with EDTA was drained from the cephalic vein for a complete blood picture. The suspected nodules are firm painful to touch and had progressively worsened, and developing purulent discharge from draining tracts. Moreover, The nodules had a large, irregular, non-coalescing shape extending from the shoulder area down to the flanks region, Furthermore, The skin overlying the

---

Date of Submission: 28-11-2020

Date of Acceptance: 13-12-2020

---

### I. Introduction

Panniculitis, Its inflammation of the subcutaneous fat tissues in cats and dogs (the panniculus). The inflammation could be infected or non-infected in its origin, However, the systemic signs are always associated with the skin lesions(1). Cats at any age, sex, or breed may be affected by panniculitis(2).

It has been documented that, the most important infectious causes of panniculitis in both dogs and cats are *Nocardia* spp, *Actinomyces* spp including *Actinobacillus lignieresii*, Moreover, The saprophytic soil fungi and deep and systemic fungal infections, such as *Pythium* spp., *Sporothrix* spp., *Blastomyces* spp., *Coccidioides* spp., *Cryptococcus* spp., *Histoplasma* spp. and *phaeohyphomycosis*. was all play a good role. Furthermore, mycobacterial infections have to be ruled out in all cases of panniculitis(3). On the other hand, Different diseases can result in non-infectious panniculitis, and an idiopathic form has also been recognized (sterile nodular panniculitis). The most common conditions implicated are, Post-injection inflammation (corticosteroids, vaccines), Pancreatic disease, Immune-mediated diseases (Lupus erythematosus), Vasculopathy, Trauma, Drug-eruption, Vitamin E deficiency, and Neoplastic diseases (multicentric mast cell tumors, cutaneous lymphosarcoma) (4).

The most common lesions which could be seen in diseased cats are deep-seated nodules, mostly accompanied by draining tracts discharging an oily fluid if affect the trunk(5,6), Moreover, Another, subcutaneous masses are most commonly found on the ventral abdomen (in cases of mycobacterial infection), or on the dorsal neck (if the post-injection reaction is the cause) or even the limbs (other etiology)(7).

Disease cats show systemic signs, including anorexia, high body temperature, lethargy, and depression, which are often associated with skin changes. These symptoms often wax and wane with an increase in systemic signs often preceding the development of new skin lesions(1).

It was shown that Early and localized lesions are often freely movable under the skin. The nodules can be soft or hard and vary in size. The overlying skin can be normal, yellow, brown, or red and often becomes necrotic and ulcerates, forming draining tracts. Alopecia may be present and scar tissue can form, causing permanent alopecia in the affected areas(8).

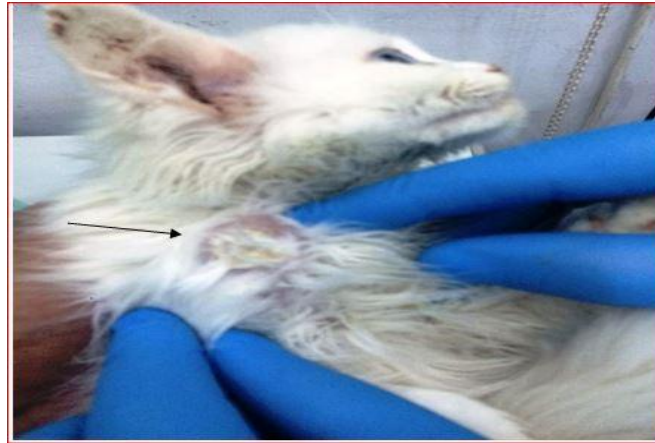
### II. Animal History And The Presented Case

A six months local cat breed was presented to the Consultant Veterinary Clinic, College of Veterinary Medicine, University of Basrah, with a history of .anorexia, fever, depression, and multiple clear firm subcutaneous nodules on the shoulder area of both sides. Complete Clinical examination has been applied to the diseased cat and a clinical diagnosis of panniculitis was suspected.

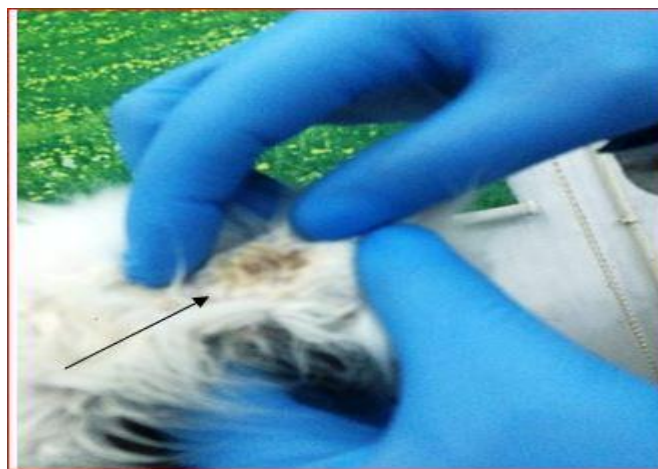
Three milliliters of blood mixed with EDTA f was drained from a cephalic vein for a complete blood picture using Coulter counter from the USA.

### III. Results

The suspected nodules are firm painful to touch and had progressively worsened, and developing purulent discharge from draining tracts. Moreover, The nodules had large, irregular, non-coalescing shape extending from the shoulder area (Fig.1) down to flanks region, Furthermore, The skin overlying the nodular mass was dotted with crusted draining tracts(Fig.2) .



**Fig. 1:** A clear panniculus subcutaneous nodules on the shoulder area



**Fig. 2:** Non-coalescing nodule .The skin overlying the nodular mass was dotted with crusted draining tracts

Diseased cat show high body temperature 39.7C, increase respiratory rate 41/ min. As well as increase heart rate 145/min. Table 1.

**Table 1:** Vital clinical signs of the diseased cat

Parameters	Diseased cat	The normal Reference (6)*
Body temperature c	39.7	38.5
Respiratory rate /min	41	22
Heart rate / min	145	110

(6)\*

Moreover, the hematological parameters of the diseased cat indicated Leucocytosis with Nutrophelia. Table.2

**Table 2:** Hematological parameters of the diseased cat

Parameters	Diseased cat	The normal Reference (6)*
RBC x 10 <sup>6</sup>	5.4	4.7-9.2
Hb g/dl	13.3	12.2-20.2
PCV %	57	36-54
TLC x 10 <sup>3</sup>	16.3	4.0-15.5
Lymphocyte %	28	12-30
Neutrophils %	65	51-58
Eosinophiles %	2	2-12
Monocytes %	5	3-10
Basophiles %	0	0.4-0.8
Total platelet counts x10 <sup>3</sup>	240	170-339

(6)\*

#### IV. Discussion

To our knowledge, this is the first reported case of clinical panniculitis registered in a cat in Basrah, Iraq.

Panniculitis is uncommonly seen in both cats and dogs. Although a large number of organisms can cause infectious panniculitis(1,9). Moreover, different systemic diseases can also cause non-infectious panniculitis. Of the non-infectious cases, sterile nodular panniculitis is the most common type(2).

The cutaneous lesions in cats are most commonly multiple, subcutaneous pyogranulomas with fistulous tracts associated with purulent or serosanguineous drainage are common and previously mentioned by (2,10).

The basic pathophysiological feature of the disease starting with inflammation of subcutaneous fat followed by damage to the fat cells releases lipid into extracellular space(Lipid is converted to fatty acids and these are potent inflammation inducers), Moreover, Granulomatous reactions to fatty acids will be developed which could be sterile or infectious(11).

Regardless of the cause, inflammation of the subcutaneous fat looks the same on histological examinations. The inflammatory reaction may be granulomatous, pyogranulomatous, necrotic, eosinophils or lymph-plasma-histiocytic(11). Infectious agents can sometimes be seen on histopathology, but culture is always indicated to rule out infectious diseases. Special stains sometimes help identify potential causative organisms(2,3).

It has been shown that Mycobacterial panniculitis refers to the clinical syndrome characterized by chronic infection of the sub-cutis and skin of cats. In cats, The disease typically follows contamination of wounds. The bacterial species involved appear to have a predilection for adipose tissue(12,13).On the other hand, it was also documented that, Vitamin E deficiency was previously documented as a cause of fat necrosis/panniculitis in dogs and cats fed fish-based diets, However, the appearance of panniculitis due to vitamin E deficiency decreased because commercial foods are usually supplemented with vitamin E(14,15).

It was documented that, only eight cases of human infection and three cases of feline infection have been reported in the literature. Half of the infections in people occurred three months after surgery. The three previously reported cases of Mycobacterium thermoresistibile infections in cats included two cats with skin infections and one with pneumonia(16).

#### Treatment and Management

The advice of treatment has different choices, However, the use of non-steroid anti-inflammatory drugs such as ibuprofen to suppress the inflammation and reduce the feeling of pain, Moreover, broad-spectrum antibiotics for controlling the infection was always advised. Despite that, Sometimes the nodules will heal on their own without treatment(17).

#### References

- [1]. Yamagishi, C., Momoi, Y., Kobayashi, T., Ide, K., Ohno, K., Tsujimoto, H. and Iwasaki, T. (2007) A retrospective study and gene analysis of canine sterile panniculitis. *Vet. Med. Sci.* 69(9):915-24.
- [2]. Gross, T. L., Ihrke, P. J. et al., (2005) Diseases of the panniculus. In: *Skin Diseases of the Dog and Cat*, 2nd edn., pp. 538-58. Blackwell, Oxford.
- [3]. Malik, R., Wigney, D.I, Dawson, D, et al. (2000) Infection of the subcutis and skin of cats with rapidly growing mycobacteria: a review of microbiological and clinical findings. *J. Feline Med. Surg.* 2: 35-48.
- [4]. Scott, D. W., Miller, W. J. and Griffin, G. E. (2001) Miscellaneous skin diseases. In: *Muller & Kirk's Small Animal Dermatology*, 6th edn., pp. 1156-62. WB Saunders, Philadelphia.
- [5]. Murillo, J., Torres, J., Bofill, L., et al. (2000). Skin and wound infection by rapidly growing mycobacteria: An unexpected complication of liposuction and liposculpture. *Arch Dermatol.* 136:1347-1352.
- [6]. Ettinger, S.J and Feldman, E.C. (2005). *Text book of Veterinary Internal Medicine: Disease of Dog and Cat* (6th edn). In: WB Saunders (Ed.), Philadelphia, USA
- [7]. Shojaei, H., Heidarieh, P., Hashemi, A, et al. (2011). Species identification of neglected non-tuberculous mycobacteria in a developing country. *Jpn. J. Infect. Dis.* 64: 265-271.
- [8]. Niza, M. M., Vilela, C. L., & Ferreira, L. M. (2003). Feline pansteatitis revisited: Hazards of unbalanced home-made diets. *Feline Med. Surg.* 5(5), 271- 277.
- [9]. Gear, R. N. A., Bacon, N. J., Langley-Hobbs, S., et al., (2006). Panniculitis, polyarthritis and osteomyelitis associated with pancreatic neoplasia in two dogs. *Small Anim. Prac.* 47:400-404.
- [10]. Malik, R., Wigney, D.I, Dawson, D et al. (2000). Infection of the subcutis and skin of cats with rapidly growing mycobacteria: a review of microbiological and clinical findings. *Feline. Med. Surg.* 2: 35-48.
- [11]. Declercq, J., de Bosschere, H., Schwarzkopf, I., & Declercq, L. (2008). Papular cutaneous lesions in a cat associated with feline infectious peritonitis. *Vet. Dermatol.* 19(5): 255- 258.
- [12]. Vishkautsan, P., Reagan, K.L., Keel, K and Sykes, J. E (2016). Mycobacterial panniculitis caused by Mycobacterium thermoresistibile in a cat. *Feline. Med. Surg. Open Reports* 1-7.
- [13]. Lewis, T.D., Kunkle, G.A. (1998). Opportunistic rapid-growing mycobacterial infections. In: *Greene CE, ed. Infectious Diseases of the Dog and Cat*. 2nd ed. Philadelphia: WB Saunders. 322-24.
- [14]. Harada, H., Endo, Y., Sekiguchi, M. et al (2009). Cutaneous nocardiosis in a cat. *Journal of Veterinary Medical Science*, v.71, p.785-787, 2009.

- [22]. Steff, M., Nautscher, N., Kropftl,A., Granvog,M.(2020).Nodular panniculitis in a cat with high tocopherol concentration in serum .(Case report).Vet.Med.Sci.00:1-5.
- [23]. Foster, S.F., Martin, P., Davis, W., et al(1999). Chronic pneumonia caused by *Mycobacterium thermoresistibile* in a cat. Small Anim. Pract. 40: 433–438.
- [24]. Kano R., Okabayashi K., Nakamura, Y., Fujiwara, K.,Hasegawa, A., Sasaki, Y. (2006). Systemic treatment of sterile panniculitis with tacrolimus and prednisolone in dogs. Vet. Med. Sci. 68 (1) : 95-6.

KAMAL M. AL-SAASD. “A Clinical Case of Panniculitis in a Cat (Case Report).” *IOSR Journal of Agriculture and Veterinary Science (IOSR-JAVS)*, 13(12), 2020, pp. 27-30.