

Treatment of ventral abdominal hernia in a cockatiel (*nymphicus hollandicus*)*

S.Melek, S.Unsaldi,E. Karabulut

Department of Surgery, Veterinary Faculty, Bingol University, Bingol, Turkey

*It was presented in International Congress on Medical and Health Sciences Research.11-14 July Bandirma, Turkey.

Abstract: In this case, It was aimed to sharing the results obtained and treatment of ventral abdominal hernia in 1 year old female cockatiel brought to Bingol University Veterinary Faculty Surgery Clinic.

In anamnesis; It was learned that a mass about the size of a hazelnut appeared in the abdominal region 6 months ago. In palpation examination, reponibility and compressibility were detected and was suspected of hernia abdominalis. Ketamine-HCL (Ketasol 10%, Richter Pharma AG, Austria) was administered intramuscularly (IM) at a dose of 35 mg / kg for general anesthesia of cockatiel. Routine asepsis antisepsis procedures were performed after removing the feather in the abdomen of the parrot. During operative intervention;It was observed that the intestines herniated and the mesentery adhered to the abdominal wall. Not detected hernia passage. The herniated intestines and the adherent mesentery were bluntly separated and rejected into the abdomen. The abdomen was closed with routine suture material and techniques and the operation was completed. In the postoperative period, 10 mg / kg orally Enrofloxacin (Baytril 10% oral solution, Bayer, Germany) was given for 3 days.

No recurrence or infection was observed postoperatively. The patient recovered.

Keywords—Cockatiel, hernia, abdomen,treatment.

Date of Submission: 26-07-2019

Date of acceptance: 12-08-2019

I. Introduction

The etiology of abdominal hernia in poultry is unknown. however, it has been proposed to be congenital or acquired¹.Although abdominal hernia is not common, it is observed especially in obese female birds².Hematomas and lipomas are usually observed in abdominal region and radiography or ultrasonography is used in differential diagnosis³.It has been reported that abdominal hernia in poultry is not similar to mammalian hernia, and the specific hernia passage is not significant. Instead, thinning and gradual separation of muscle fibers are reported⁴.

If possible, the bird should be converted to a formulated diet before surgery in order to achieve significant weight loss. Reproductive activity can be reduced by hormonal and behavioural manipulation before surgery. These two treatments may be sufficient to reduce the size of the hernia and avoid surgery⁵. The surgical procedure of abdominal hernia in parrots is not a simple procedure. The operator should evaluate both the patient and the hernia, and identify ways to minimize or prevent possible complications and effects. This increases the chances of a successful outcome in both the short and long term⁶.

In this case, It was aimed to sharing the results obtained and treatment of ventral abdominal hernia in 1 year old female cockatiel brought to Bingol University Veterinary Faculty Surgery Clinic.

II. Case Report and Discussion

In anamnesis; It was learned that a mass about the size of a hazelnut appeared in the abdominal region 6 months ago (Figure 1A). In palpation examination, reponibility and compressibility were detected and was suspected of hernia abdominalis (Figure 1B). Ketamine-HCL (Ketasol 10%, Richter Pharma AG, Austria) was administered intramuscularly (IM) at a dose of 35 mg / kg for general anesthesia of cockatiel. Routine asepsis antisepsis procedures were performed after removing the feather in the abdomen of the parrot. During operative intervention;It was observed that the intestines herniated and the mesentery adherent to the abdominal wall (Figure2).Not detected hernia passage. The herniated intestines and the adherent mesentery were bluntly separated and rejected into the abdomen(Figure 3). The abdomen was closed with routine suture material (4/0 Polyglactin 910 coated Vicryl, Ethicon) and techniques and the operation was completed(Figure 4). In the postoperative period, 10 mg / kg orally Enrofloxacin (Baytril 10% oral solution, Bayer, Germany) was given for 3 days.

No recurrence or infection was observed postoperatively. The patient recovered completely without complications.

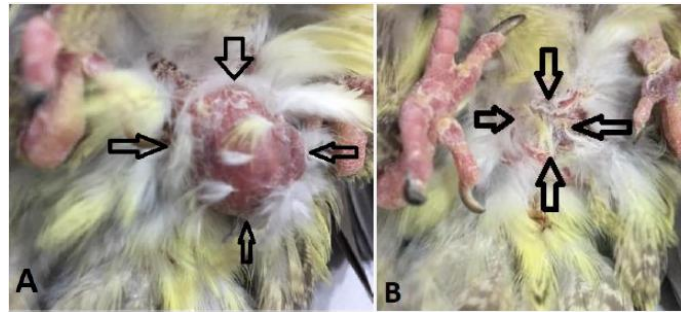


Figure 1: Appearance of the mass in a female cockatiel (A). Rejection of abdominal hernia in supine position (B).

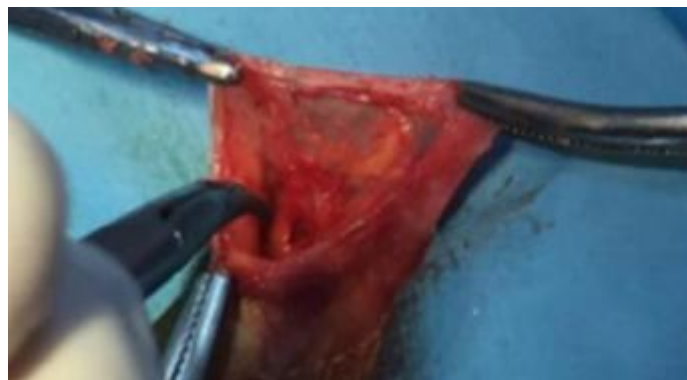

Figure 2: Appearance of intestines and mesentery in hernia sac.

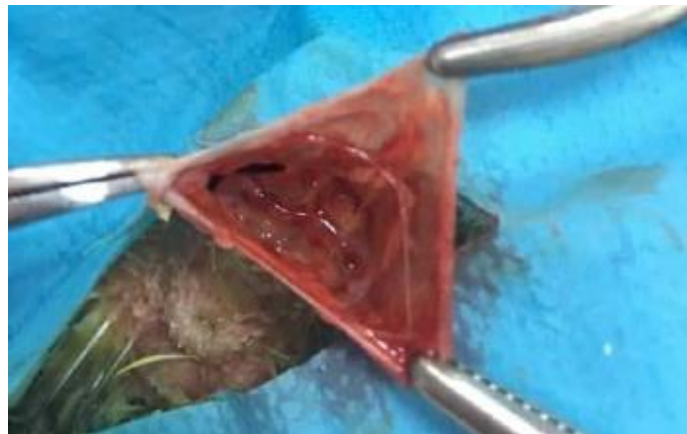


Figure 3: Appearance of herniated intestine and mesentery rejected into the abdomen.



Figure 4: Postoperative appearance of abdominal region and Cockatiel.

There are very few articles about abdominal hernia in birds. Abdominal hernia is caused by a combination of increased intra-abdominal pressure (fat, ascites, organomegaly) and weakened muscles due to hormonal influences, obesity, lack of exercise and chronic malnutrition. It is commonly associated with females during the breeding season, as enlargement of the ovary and oviduct increases intra-abdominal pressure. Although most hernias occur on the ventral midline, they can also be seen on the lateral body wall and dorsal to the vent^{5,7}. In this case, abdominal hernia was detected in the ventral midline. Herniated organs were intestine and mesentery.

It has been reported that abdominal hernia in poultry is not similar to mammalian hernia, and the specific hernia passage is not significant. Instead, thinning and gradual separation of muscle fibers are reported. Skin ulcers and bleeding may occur in large hernias^{4,7}. In our case, hernia passage, skin ulcers and skin bleeding could not be detected.

The short-term prognosis of hernia repair is good, so long as causative factors have been identified and remedied and the surgical plan minimizes the risks associated with the reduction and repair. The long-term prognosis is more guarded, as recurrence is not uncommon. If reproductive activity continues there is the added risk of yolk-related peritonitis developing⁶. No recurrence or infection was observed postoperatively. The patient recovered completely without complications.

III. Conclusion

It was concluded that abdominal hernia rarely seen in cockatiel with minimally invasive surgical approach can be curable.

References

- [1]. Dar KH. Surgical management of abdominal hernia in a duck (*Anas platyrhynchos*): A case report. *Mathews Journal of Veterinary Science*, 2016;1(1):002.
- [2]. Jahromi AR, Nazhvani SD, Haddadi S. Ventral abdominal hernia in a common Myna (*Acridothera tristis*) - a case report. *Veterinarski Arhiv*, 2009; 79(6): 621-625.
- [3]. Coles BH. *Avian medicine and surgery*. 2. Edition. Oxford, Blackwell Science Ltd. 1997.
- [4]. Forbes NA. Avian gastrointestinal surgery. *J. Exot. Pet. Med.* 2002; 11:196-207.
- [5]. Doneley B. *Avian medicine and surgery in practice*. London, Manson Publishing, 2010; 172-263.
- [6]. Doneley B. Considerations for Hernia Repair in Parrots. Association of Avian Veterinarians Australasian Committee, Annual Conference Sydney 2015; 23:28-30.
- [7]. MacWhirter P. A review of 60 cases of abdominal hernias in birds. *Proc Annu Conf Assoc Avian Vet.* 1994;27-37.

S.Melek. "Treatment of ventral abdominal hernia in a cockatiel (*nymphicus hollandicus*)".
"IOSR Journal of Agriculture and Veterinary Science (IOSR-JAVS) 12.8 (2019): PP- 34-36.