

Morphological study of the respiratory system of bungo fish (*Glossogobius Cf. Aureus*) from Lake Tempe, South Sulawesi, Indonesia

Ade Andrew Samudera Pinontoan¹, Wahyuni², Andi Tamsil³,
Dwi Kesuma Sari^{1*}

¹(Study Program of Veterinary Medicine, Faculty of Medicine, Hasanuddin University, Makassar, South Sulawesi, Indonesia)

²(Disease Investigation Centre Maros, South Sulawesi, Indonesia)

³(Faculty of Fisheries and Marine Sciences, Muslim University of Indonesia, Makassar, South Sulawesi, Indonesia)

Corresponding Author's: Dwi Kesuma Sari

Abstract: Bungo fish (*Glossogobius Cf. aureus*) is native species from Tempe Lake, South Sulawesi. This study was conducted with the aim to observe anatomical and histological of respiratory system of bungo fish. This study showed several characteristics such as the configuration of gills filament for the "V" shape without septum, operculum located adjacent to the pectoral, membrana branchialis converged with isthmus with a narrow slit, and short gills filters, however the fish did not have additional breathing organ and only depended on countercurrent flow system to obtaining oxygen. Histological observations showed some characteristics such as afferent arterioles at the end of the primary lamella and efferent arterioles at the base of the primary lamella, single layer of epithelial cells along the surface of the lamella, chloride cells between base of the secondary lamella, mucous cells at the base of secondary lamella, sustaining cartilage tissue at the base of the primary lamella, venous sinuses along the primary lamella which was forwarded to the secondary lamella through capillaries in the secondary lamella. Generally, respiratory system structure of the bungo fish was similar to the teleostei fishes.

Keywords: bungo fish, respiratory system, gills, anatomy, histology

Date of Submission: 25-01-2018

Date of acceptance: 09-02-2018

I. Introduction

Lake Tempe is one of the big lakes located in South Sulawesi Province, Indonesia, precisely in Wajo Regency (70% of part areas), Sidrap Regency and Soppeng Regency. There are many fish species in the lake such as goldfish (*Cyprinus carpio*), nilem fish (*Osteochillus hasselti*), cork fish (*Ophiocephalus striatus*), Siamese gourami or snake-skin gouramy (*Tricogaster pectoralis*), bungo fish, fishpond (*Helostoma temmincki*), and nile tilapia fish (*Oreochromis niloticus*) [1]. One interesting thing is the bungo fish (*Glossogobius Cf. aureus*) is an indigenous species on Lake Tempe, but it does not get much attention either by researchers and local governments that lead to minimal conservation efforts. This can be seen by the lack of research on germplasm resources, conservation and efforts of local governments in the form of research and protection of populations and their habitats.

Water biota that can be developed as a cultivation commodity, both freshwater biota and marine biota, the number is still very much. Some species are endangered, while cultivation technology has not been mastered. For example, bungo fish or beloso fish, this fish is one of the important fish in Tempe lake, South Sulawesi which is increasingly pressed due to intensive catching, introduction and degradation of its habitat [1]. The information obtained shows no publication of the anatomical and histological features of the *Glossogobius Cf. aureus*, whereas the respiratory system is one of the systems present in the metabolism of living things.

The fish respiration system consists of gills, operculum and additional breathing tools for breathing in the air such as labyrinth in gurami (Subordo *Anabantoidae*), arborescent organs in catfish (*Siluriformes* order), diverticula in cork fish (*Channa striata*), lungs in Lungfish (*Dipnoi subclassis*), and fish from the family *Notopteridae* and family *Phractolaemidae* have alveolar air sacs [2, 3]. In teleostei fish, water enters the pharynx from the mouth, then passes through the gill filaments and then into the inner wall of the operculum to exit through the opening of the caudal portion of the operculum [4]. Gill plays a role in the process of respiration, acid-base balance, ionic and osmotic regulation due to branchial epithelium network which becomes

the place of active transport between organism and environment. Gills is the first organ to filter water entering the body [5].

Water is a major part of the fish environment but unfortunately the water is easily contaminated by harmful substances, in addition there are also parasites and microbial pathogens that can disrupt the respiratory system in the fish. The organs involved in the respiratory system of the fish are susceptible to water contamination as well as infectious diseases. Therefore, observation of normal anatomy and histology obtained from this fish is very necessary as the basic data for clinical and pathological interest due to pollution, parasitic disorders and pathogenic microbes that occur in bungo fish. This study discusses the anatomical and histological features of the bungo fish respiration system sampled from Tempe Lake, Tempe Sub-district, Wajo Regency, South Sulawesi Province. The observational study of anatomic and histologic features of the organ is described descriptively.

II. Materials And Methods

The study was conducted in December 2014 until January 2015. The location of the study at Anatomy and Histology Laboratory of Study Program of Veterinary Medicine Hasanuddin University and Pathology Laboratory of Disease Investigation Centre Maros. The material used is 6 bungo fish with average weight 12 gram. Bungo fish obtained from Lake Tempe by capture. Fish samples were then stored in formalin p.a 10%. The researchs were divided into 3 main procedures, namely the observation of anatomy, histology, and data analysis. In anatomy observation, fish are placed on fixation tray then photographed from 4 angles ie dorsal, ventral, lateral and anterior. For observation of the head and mouth cavities, the fish head is opened by cutting sagittally on the cranial area without cutting the gills and then being observed and photographed from the lateral direction. After that, a transversal cutting in the maxilla after the eye from the anterior angle of the fish is observed and photographed from the dorsal and anterior angles and the last transversal cutting on the mandible corresponding to the previous cut in the maxilla section and then observed and also photographed from the anterior angle. For further observation of the gills removed from the whole fish body and were observed from 3 angles of dorsal, ventral and lateral and then photographed.

The gill organs were separated from the sample and then fixed in a 10% formalin solution followed by dehydration with stratified alcohols, clearing with xylol and embeded in paraffin. The tissue in paraffin blocks were cut with a thickness of 4 µm using a microtome, then placed on the object glass and stored in an incubator with a temperature of 40°C for 24 hours. Samples were stained with Mayer's Hematoxylin Eosin (HE) for standard coloring to see the bungo fish structure. After staining, dehydration, cleansed in xylol, the samples were then mounting and ready for observation [6].

The observations were performed under a microscope, with 10x and 16x subjective lens magnification as well as an objective lens of 4x, 10x, and 40x. Photograph of the samples were done using a digital camera (Canon IXUS 80 IS, Japan). The observed portion is a gill composed of primary lamellae and sekunder, lacuna along with its constituent cells such as pillar cells, epithelial cells, mucus cells, undifferentiated cells, and chloride cells. Data analysis used is descriptive qualitative data analysis. In this method will explain the description of anatomy and histology in the respiration system of bungo fish.

III. Results And Discussion

The shape of a bungo fish's mouth falls into the category of the terminal mouth with a prominent lower jaw. The operculum on the bungo fish consists of a large *os.operculare* and with a triangular bone, *os.preoperculare* form of the letter "L" and located on the anterior portion of the *os.operculare*, *os.suboperculare* located in the *posteroventral* of *os.operculare*, and *os.interoperculare* which is the ventral part of *os.preoperculare*. The location *os.preoperculare* in bungo fish more away from the eyes. The branchialis membrane of the bungo fish joins the isthmus with a narrow gap (Fig. 1).




Fig. 1. Bungo fish with dorsal view observation (A), ventral (B), anterior (C) and left lateral view (D). 1. nostril; 2. *os.operculare*; 3. *os.suboperculare*; 4. *os.preoperculare*; 5. *membrana branchialis*; 6. *radii branchialis*; 7. pectoral fin; 8. *os.interoperculare*; 9. *m.apparatus mandibula*; 10. *isthmus*; 11. *pelvis fin*.

On observation of the head cavity no additional respiratory equipment was found to support the fish can breathe in the air. The number of *arcus branchialis* of bungo fish is 4 pairs. Gill filaments in bungo fish are in the form of a "v" letter without a septum or separator on the two pairs of filaments that exist along the branchial arcus. The bungo has a small, spiral-shaped gill filter which is paired along the branchial arcus and each pair forms like a loose pear along the first branchial arcus in the anterior section then becomes more closely arranged in the next branchial arcus to the fourth *branchialicarcella* at the posterior side (Fig. 2)

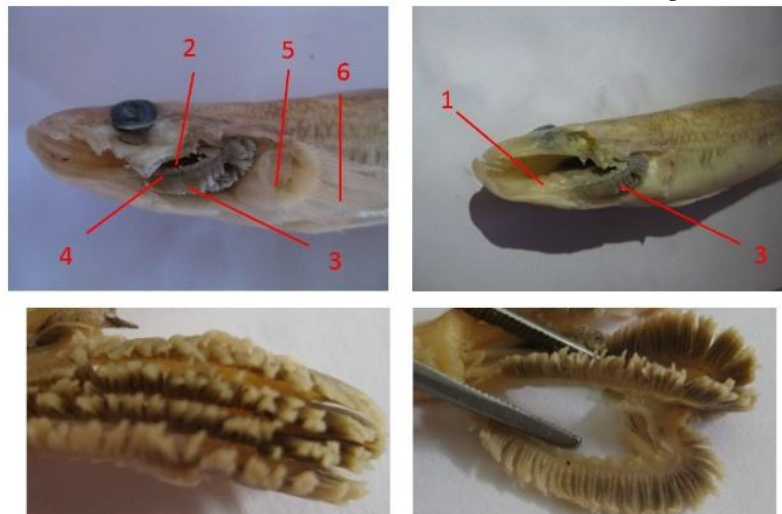


Fig. 2. Sagittal view of crania area of the gills of bungo fish. 1. Gills support muscles; 2. Gills screen; 3. gill filamen; 4. *arcus branchialis*; 5. *pectoral fin support*; 6. *pectoral fin*

In the mandible observation of the dorsal direction there are blood vessels above the *hyoideum*, this blood vessel is the main blood vessel for blood flow from the gill to the heart. Of this form is certain blood from the gills which receive and distribute oxygen flow to the blood vessels in the mandible during which the diffusion of oxygen through a system of countercurrent flow where the filaments gill is passed the incoming water from the oral cavity, the water flow leads to caudal while the blood flow to receive and transport oxygen to the heart leads to the cranial (Figs. 3 and 4).




Fig. 3. Bungo fish with transverse cuts in the transition area between the oral and pharyngeal cavities with anterior observation (A) and transverse cuts of the mandible with posterior observation (B). 1. gills; 2. cartilago palate; 3. pectoral muscle; 4. septum separating pectoral muscle; 5. blood vessels; 6. *hyoideum*; 7. transitional septum on the pectoral fin muscle; 8. *m. apparatus mandibulae*; 9. muscles around the *hyoideum*

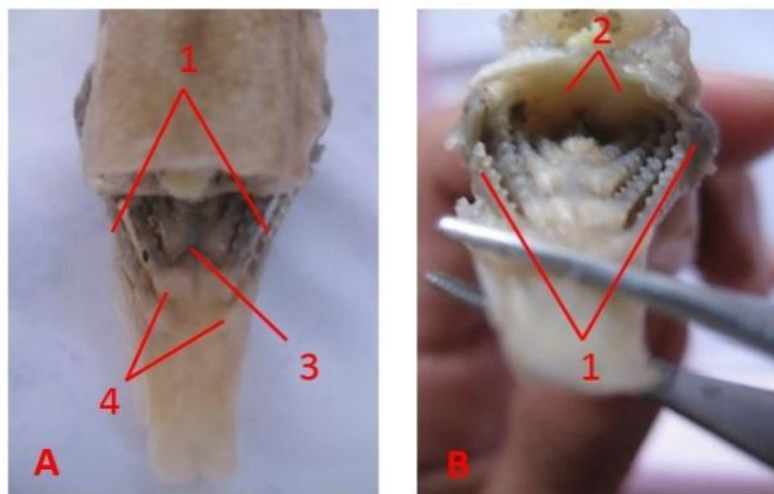


Fig. 4. Bungo fish with transverse cuts on the maxilla in the transition between the oral and pharynx with dorsal (A) and anterior (B) observations on bungo fish. 1. gills; 2. cartilago palate; 3. blood vessels; 4. gill support muscles

The bungo fish has afferent arterioles at the base of the primary *lamellae* and the efferent arterioles at the end of the primary lamella. There is a supportive cartilage network that supports primary lamella in bungo fish. The mucous cells of bungo fish in primary *lamellae* is located between each of the secondary *lamellae* bases. Chloride cells of bungo fish are located at right on the base of the secondary *lamellae*. The cells are associated with the respiratory system such as cells of the erythrocyte exist in every part of the lamella, the lamella primary erythrocytes flowing in the veins, called venous sinuses that connect afferent arterioles located at the base of the lamella primary and arterial efferent located at the end of the lamella primers and secondary lamella are present in the capillary lumen, then the outermost part is covered by epithelial cells (Figs. 5 and 6). According to other fishes, they are similarity with other fishes specially in teleost fishes [7].

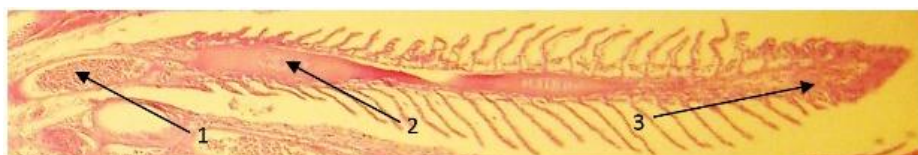


Fig. 5. Gill histology of bungo fish, magnification: 40x sagittal pieces. 1. erythrocytes in the afferent arteriole; 2. cartilage network; 3. erythrocytes in efferent arterioles

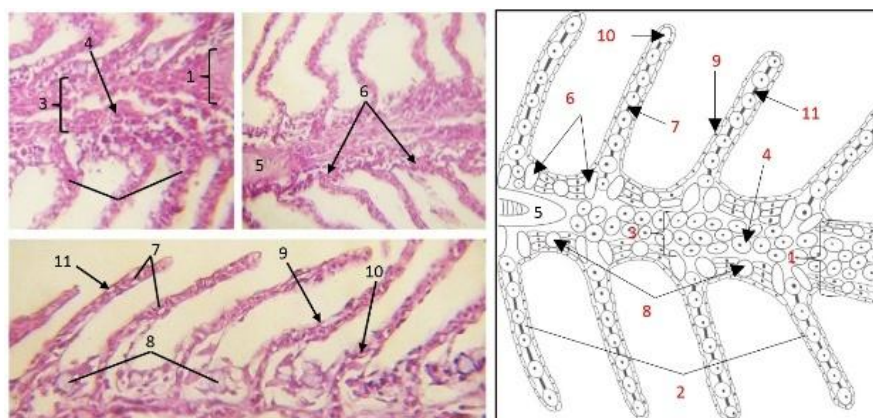


Fig. 6. Histology of the gills of bungo fish, magnification: 400x sagittal pieces and the sketches. 1. primary lamella; 2. secondary lamella; 3. venous sinus; 4. erythrocytes present in venous sinuses; 5. primary lamella support cartilage; 6. chloride cells; 7. pillar cells; 8. mucus cells; 9. epithelial cells; 10. erythrocyte cells in the capillary lumen; 11. lacuna

IV. Conclusion

Based on the results of research conducted, it can be concluded that bungo fish only rely on gills as the main respiratory organs. Bungo fish have 4 pairs of gills with gill filament shaped "v" without septum. The histology structure of gills in bungo fish is similar to that of teleostei fish in general, namely primary lamella and secondary lamella consisting of mucus cells, chloride cells, supportive cartilage tissue at the base of primary lamella, pillar cells, and erythrocytes cells along the capillaries and venous sinus. The bungo fish has afferent arterioles at the base of the primary lamellae and the efferent arterioles at the end of the primary lamella. Generally, respiratory system structure of the bungo fish was similar to the teleostei fishes.

Acknowledgements

The authors would like to thank the Histology and Pathology Laboratory of Veterinary Medicine Program of Hasanuddin University Faculty of Medicine and Disease Investigation Centre Maros for doing the the research.

References

- [1]. A. Tamsil. *Study some characteristics of prespawning reproduction and possible spawning of bungo fish (Glossogobius cf. Aureus) at Lake Tempe and Lake Sidenreng South Sulawesi*, Doctoral Diss., Bogor Agricultural University, Bogor, Indonesia, 2000
- [2]. S.A. Omar. *Iktiologi*. (Fakultas Ilmu Kelautan dan Perikanan, Universitas Hasanuddin, Makassar, 2011) (ID)
- [3]. G.S. Helfman, B.B. Collette, D.E. Facey, B.W. Bowen. *The Diversity of Fishes, Biology, Evolution, and Ecology*. (Wiley-Blackwell, Hoboken, USA, 2009)
- [4]. D.H. Evans, P.M. Piermarini, K.P. Choe. The Multifunctional Fish Gill: Dominant Site of Gas Exchange, Osmoregulation, Acid-Base Regulation, and Excretion of Nitrogenous Waste. *Physiological Reviews*, 85, 2005, 97–177.
- [5]. P.C. Withers. 1992. *Comparative Animal Physiology*. (Saunders College Publishing, Londong, UK, 1992).
- [6]. W.J. Bacha and L.M. Bacha LM. *Colour Atlas of Veterinary Histology* 3rd Ed. (John Willey & Sons, Ltd, Chichester, UK, 2012)
- [7]. F. Takashima and T. Tibiya. *An atlas of fish histology: normal and pathological features*. (Kodansha, Japan, 1995).

Ade Andrew Samudera Pinontoan "Morphological study of the respiratory system of bungo fish (Glossogobius Cf. Aureus) from Lake Tempe, South Sulawesi, Indonesia." *IOSR Journal of Agriculture and Veterinary Science (IOSR-JAVS)* 11.2 (2018): PP 12-16.