

The Effect on Production Loss of Dental Disorders in Adult Goats*

Ibrahim Canpolat, Enis Karabulut, Sema Cakir

Department of Surgery, Veterinary Faculty, Firat University, Elazig, Turkey

* Oral Presentation: IGA 2016, 12th International Conference on Goats, 25-30th September 2016 Antalya, Turkey

Abstract: In this study aimed to investigate dental disorders of goats. The study was performed on 100 goat cadaver heads and 100 goats. In Group I; goat cadaver heads (n=100) were examined at the slaughter house on Elazig city in Turkey. In Group II; It was performed oral examination of goats (n=100) in Firat University Animal Hospital and farms. The most prevalent dental abnormalities were overgrown or abnormally erupted and loss of the incisor teeth, excessive transverse ridging of the occlusal surface, occlusal wear, excessive occlusal points, the presence of diastemata, gingival recession and peridontal pocketing, missing teeth, molar root abscessation in cadaver heads. Dental disease detected at 33 (33%) cases in slaughterhouse. Overgrown and excessive wear of incisors, tooth loss, tooth fracture, gingival recession and periodontal pocketing, diastemata, missing teeth, occlusal wear abnormalities, excessive occlusal points and sharp edged teeth, and molar root abscessation detected at 34 (34%) dental disease cases in animal hospital. In clinical examination; 15 patients showed symptoms and 19 patients no showed symptoms of the dental diseases. The sharp lateral borders on the molar teeth upon oral examination was determined frequently in goats. This is a very common condition in adult goats in Elazig region. When sharp-edged teeth and other dental disorders were corrected, it was observed an increase in live weight gain and milk yield of the goats.

Keywords: Dental, disorder, goat, loss, production.

Date of Submission: 01-08-2017

Date of acceptance: 14-08-2017

I. Introduction

Correct dentition is of critical importance to the maintenance of body condition/weight gain in sheep and goat. The eruption of the milk teeth and permanent teeth, occur in mammals following a determined order and in chronologic periods relatively independent of the animal's physiological state¹. Small ruminants appear to have an outside life span of 20 to 25 years with the average somewhere in the mid to upper teens. If poor body condition is a presenting complaint in the adult small ruminant, a thorough dental exam is warranted². Ruminants have narrow mouths that do not open very far, thus hindering visual exam of the molars. Careful palpation through the cheeks will give you preliminary information, but a thorough oral exam will require use of a mouth speculum, gag or bite block (either homemade or designed for sheep), a good flashlight or headlamp, and sedation³.

Dental disorders in goat and sheep can result in a range of clinical presentations (weight loss, abnormal appearance of incisors, cud-staining, swelling of the jaw, malocclusion of the jaw). Overgrown, loss of the incisor teeth and excessive wear of incisors has been reported particularly in New Zealand and Australia⁴. Elongated incisors can result in incomplete or painful mastication, trauma to the dental pad or soft tissues, or abnormal appearance of the rostral face region. They can best be reduced with the patient sedated. Irregular or sharp occlusal points will manifest either as painful or abnormal mastication, or when chronic, as weight loss secondary to incomplete or painful chewing. Extensive wear, periodontal disease, or loss of the incisor teeth and molars is common particularly in older animal⁵. Correlations between body score and incisor wear in sheep are low but between body score and molar loss are high. In sheep, nutritional factors including vitamin and mineral levels do not appear to be a predisposing cause of periodontal disease; rather it begins as a localized bacterial plaque-induced gingivitis that progresses to damage of the periodontal ligaments and eventual tooth loss⁶. Tooth root abscesses may present as firm swellings along the jaw line with or without the presence of a superficial draining tract³. Dental disorders often result in decreased milk production and to cause weight loss can be important on both an individual goat and a flock basis.

II. Material And Methods

In this study aimed to investigate dental disorders of goats. The study was performed on 100 goat cadaver heads and 100 goats. In Group I; goat cadaver heads (n=100) were examined at the slaughter house on

Elazığ city in Turkey. In Group II; It was performed oral examination of goats (n=100) in Firat University Animal Hospital and farms.

Dental examinations were performed by restraining the head and retracting the lips. Evaluation was made of the number, size and shape of the incisors and their occlusion with the dental pad. Also, evidence of gum inflammation or abnormalities of the enamel, grass impaction and spaces left by missing teeth were recorded. A crude assessment of the alignment and angles of the rostral cheek teeth were made using a dental gag and a torch.

III. Results And Discussion

Age determination was made in goats with the examination of the incisive teeth. The ages of the goats ranges from 1 to 5 in slaughterhouse and surgery clinic/farms.

Group I; The most prevalent dental abnormalities were overgrown (4) or abnormally erupted (5) and loss of the incisor teeth (2) (Fig. 1A), excessive transverse ridging of the occlusal surface (2), occlusal wear (5), excessive occlusal points (6), the presence of diastemata (1) (Fig. 1B), gingival recession and periodontal pocketing (5), missing teeth (1), molar root abscessation (2) in cadaver heads. Dental disease detected at 33 (%33) cases in slaughterhouse.

Group II; The most prevalent dental abnormalities were overgrown (1) and excessive wear of incisors (5) (Fig. 2), tooth loss (1), tooth fracture (2), gingival recession and periodontal pocketing (8) (Fig. 3), diastemata (1), missing teeth(1), occlusal wear abnormalities (6), excessive occlusal points and sharp edged teeth (7) (Fig. 4) and molar root abscessation (2) (Fig. 5). Dental disease detected at 34 (%34) cases in animal hospital and farms. In clinical examination; 15 patients showed symptoms and 19 patients no showed symptoms of the dental diseases.

The sharp lateral borders on the molar teeth upon oral examination was determined frequently in goats. This is a very common condition in adult goats in Elazığ region. When sharp-edged teeth and other dental disorders were corrected, it was observed an increase in live weight gain and milk yield of the goats.

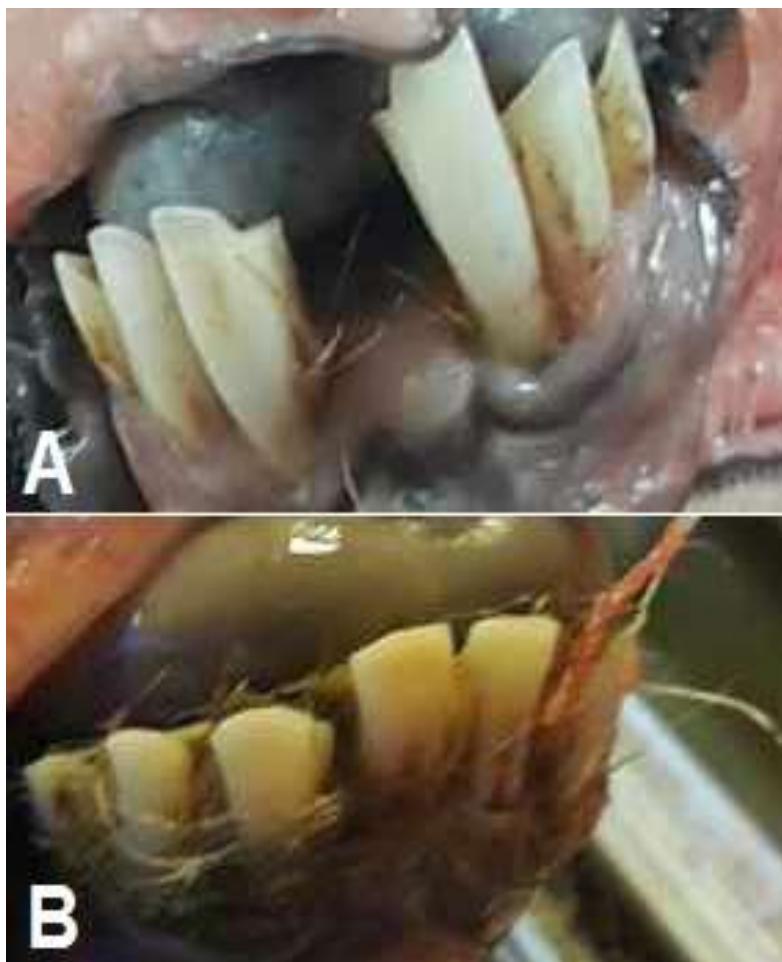


Figure 1: Appearance of loss of the incisor teeth (A), diastemata(B).

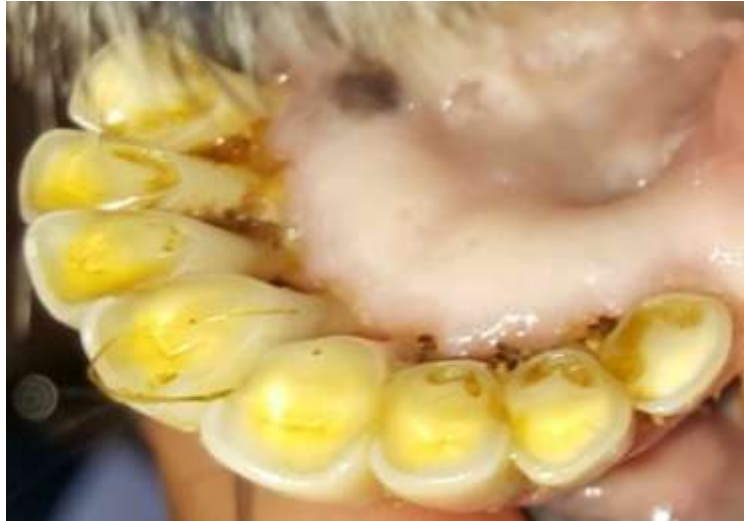

Figure 2: Dental wear

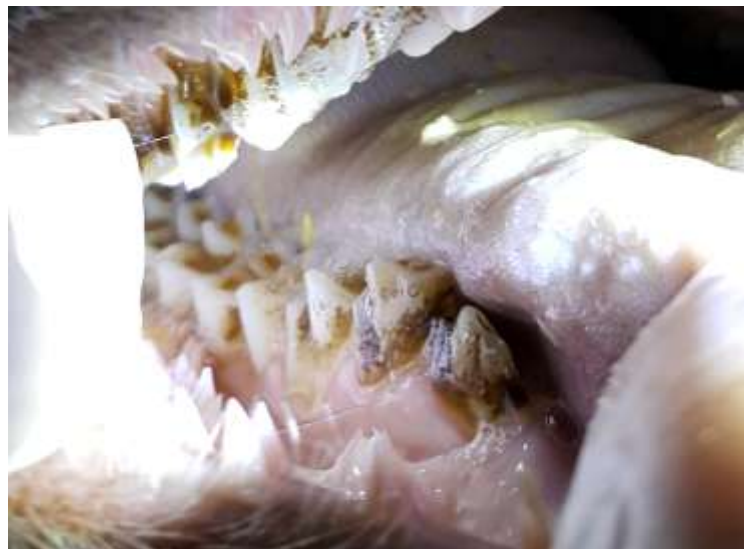

Figure 3: Gingival recession and peridontal pocketing.



Figure 4: Excessive occlusal points and sharp edged teeth

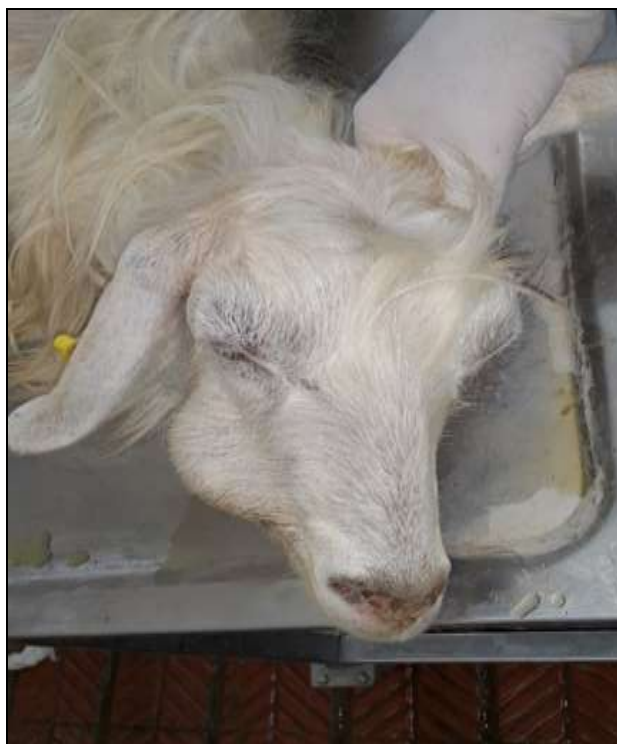

Figure 5: Molar tooth root abscess

Abnormal dental attrition occurs more commonly in sheep than in goats. The adult small ruminant may present with many of the same age-related problems as dental disease³. The highest incidence of dental attrition in sheep occurs in range ewes older than 4 years. Tooth loss can result in a 2- year decrease in the productive lives of sheep. Most sheep and goats can accommodate the loss of an incisor, but molar loss is more serious because the molars are needed for chewing roughage. Clinical signs of abnormal dental attrition include weight loss and worn, loose, or missing teeth⁷. We treated the most common dental abnormalities in small ruminants include overgrown or abnormally erupted incisors, excessive occlusal points, and molar root abscessation. Elongated incisors can result in incomplete or painful mastication, trauma to the dental pad or soft tissues, or abnormal appearance of the rostral face region⁸. Incisor loss, is an important condition of adult sheep in most sheep and goat producing countries. Affected sheep have incisors, which may be missing, while those that remain often appear very long due to regression of the gum. There may be obvious inflammation around the gums of remaining incisors and gentle palpation may reveal that some are loose. Tooth loss is thought to occur due to repeated episodes of acute gingivitis⁹. Observations were made on a small flock of 50 sheep of the native Slovenian Jezersko-Solcava breed by investigators with dental training had advanced cheektooth disease (gingival recession, periodontal pocketing, diastemata, missing teeth, occlusal wear abnormalities, food impaction, tooth mobility, tooth fracture, tooth loss and/or jaw abscessation)¹⁰.

The relationship between permanent incisor wear and age can vary with farm but in many cases the amount of wear after 5 years of age is substantial with does. Angora goat farmers need to be aware of the potential for incisor wear to affect doe production and health^{11,12}. The most frequent diseases were found gingivitis, dental tartar, and periodontal diseases in 1005 ewes¹³. In contrast to the findings of this study, excessive occlusal points and sharp edged teeth was the most common dental disorder found in a survey of 200 goats. The distribution of the dental affections incidence goats of the two areas included 33 % and 34 %, same as 34 % which the observations were made on a small flock of 50 sheep of the native Slovenian Jezersko-Solcava breed¹⁰.

IV. Conclusion

The results of this study are the first determine of dental disorders in Elazig region goats. Further research will be help to design strategies to treat the problem. According to result of in the study; when sharp-edged teeth and other dental disorders were corrected, increase in live weight gain and milk yield of the goats. Considering the economic loss of the producers, both animal health and economically should be made regular dental checkups and tooth disorders should be treated.

References

- [1]. C R Vigal and A Machordom, Tooth Eruption and Replacement in the Spanish Wild Goat, *Acta Theriologica*. 30(19), 1985, 305-320.
- [2]. P L Wolff, Geriatric small ruminants – how to keep them healthy and happy, The North American Veterinary Conference, 2007.
- [3]. D G Pugh, *Sheep and Goat Medicine*, (Philadelphia: WB Saunders, 2002)
- [4]. AL Ridler and DM West, Examination of teeth in sheep health management, *Small Ruminant Research*, 92, 2010, 92-95.
- [5]. M C Smith and D M Sherman Digestive system. In *Goat medicine*, M C Smith and D M Sherman, (Eds.) (Philadelphia: Lea &Febiger 1994)
- [6]. D M West, Dental disease of sheep, *New Zealand Vet J* 50(3)Suppl, 2002, 102-104.
- [7]. D P Gnad, D C Van Metre, S M Angelos and C Spaeth, Diagnosing weight loss in sheep: a practical approach. *Comp. Cont. Ed. Pract. Vet.*, 22(1), 2000, 16-23.
- [8]. MJ Huber, Dental surgery in small ruminants, *Proceedings of The North American Veterinary Conference*, January 17-21, Orlando, Florida, 2004.
- [9]. B J Moxham, R C Shore and B K B Berkovitz, Effects of inflammatory periodontal disease ('broken mouth') on the mobility of the sheep incisor, *Res. Vet. Sci.*, 48, 1990, 99-102.
- [10]. V Erjavec and D Crossley, Initial observations of cheek tooth abnormalities in sheep in Slovenia, *Vet. Rec.*, 167(4), 2010, 134-137.
- [11]. B A McGregor, Incisor development, wear and loss in sheep and their impact on ewe production, longevity and economics: a review. *Small Rumin. Res.*, 95, 2011, 79-87.
- [12]. B A McGregor and K L Butler, Wear of permanent incisors with age on commercial Australian Angora goat farms. *Aust. Vet. J.*, 93, 2015, 36-39.
- [13]. N Tadich and M Herrera, Dental disorders in ewes in six sheep farms in Valdivia Province, Chile. *Archivos de Medicina Veterinaria*, 23(1), 1991, 49-55.

Ibrahim Canpolat. "The Effect on Production Loss of Dental Disorders in Adult Goats* ." *IOSR Journal of Agriculture and Veterinary Science (IOSR-JAVS)*, vol. 10, no. 8, 2017, pp. 76–80.