

# Comparative Study of the Use of Selective Laser Trabeculoplasty and Argon Laser Trabeculoplasty for Open-Angle Glaucoma Management

Mohammad Alfaki\*<sup>1</sup>, Mutari Hajara Ali<sup>2</sup>, Bello Idriss Tijjani<sup>2</sup>

<sup>1</sup>College of Human Health Sciences, King Faisal University, N'djamena, Chad

<sup>2</sup>Department of Physics, Bayero University, Kano, Nigeria

---

## Abstract

Glaucoma is an irreversible eye problem that leads to vision loss. It is divided into two main different types, which are open-angle glaucoma (OAG) and angle-closure glaucoma (ACG). This study aims to evaluate selective laser trabeculoplasty (SLT) and argon laser trabeculoplasty (ALT) for treating OAG. The investigation took place in the COMSOL Multiphysics simulation environment. The eye's anterior chamber was modeled, and the two LASERs were exposed through Schlemm's canal and trabecular meshwork, which are part of the eye's anterior chamber. The thermal responses of the eye due to the absorption of the electromagnetic energy carried by the two LASERs were measured. The results indicated that a lower thermal intensity of 310K from 532nm SLT with a pulse duration of 2 ms and a heat flux of 1000 W/m<sup>2</sup> was more effective and safer for reducing intraocular pressure (IOP) with minimal risk of trabecular meshwork damage compared to the higher thermal response of 330K induced by 514nm ALT with the same pulse duration and a heat flux. The finding improves clinical practice in the ophthalmology field.

**Keywords:** Eye's anterior chamber, Schlemm's canal, trabecular meshwork, laser trabeculoplasty

---

Date of Submission: 13-06-2025

Date of Acceptance: 27-06-2025

---

## I. Introduction

Glaucoma is a multifactorial disease [1]. It is characterized by increased intraocular pressure (IOP) due to the accumulation of aqueous humor in the anterior chamber of the eye. Glaucoma suspects will have an increased intraocular pressure (IOP) of more than 21 mmHg (IOP), which is thought to cause glaucoma because it damages the blood vessels and optic nerves in the eye [2]. Diagnosis of glaucoma is mainly based on the increased intraocular pressure (IOP), medical history of the patient's family, and change in optic disc structure [3]. The main different types of glaucoma are chronic or open-angle glaucoma (OAG) and acute or angle-closure glaucoma (ACG).

OAG is one of the most common forms of glaucoma, leading to irreversible blindness globally by affecting millions of individuals. Progressive optic neuropathy, leading to the degeneration of retinal ganglion cells and subsequent visual field loss, characterizes this condition. Elevated IOP is the main risk factor for OAG progression. While conventional treatments, such as topical IOP-lowering medications, are available. However, they have potential systemic side effects with patients' adherence and high financial costs.

This study was simulated in the COMSOL multiphysics environment; the eye's anterior chamber was modeled the two LASERs were configured and exposed through the eye's anterior chamber. The results showed that a lower thermal intensity of 310K from 532nm SLT with a pulse duration of 2 ms and a heat flux of 1000 W/m<sup>2</sup> was more effective and safer for reducing intraocular pressure (IOP) with minimal risk of trabecular meshwork damage compared to the higher thermal response of 330K induced by 514nm ALT with the same pulse duration and a heat flux. These findings improve clinical practice in the field of ophthalmology.

## II. Background theory

The eyeball thermal response is solved in the COMSOL Multiphysics environment with Penné's bioheat transfer equation.

$$PC \frac{\partial T}{\partial t} = \nabla(K \nabla T) + W_p C_p (T_a - T) + q_m \quad (2)$$

---

<sup>1</sup> King Faisal University, N'djamena, Chad, College of Human Health Sciences

Corresponding Author [malfaki8@gmail.com](mailto:malfaki8@gmail.com)

where,  $P$  = Density,  $C$  = Specific heat,  $K$  = Tissue thermal conductivity,  $W_p$  = Mass flow rate of blood per unit volume of tissue,  $C_p$  = Blood's specific Heat,  $q_m$  = Metabolic heat generation per unit volume,  $T_a$  = Temperature of arterial blood,  $T$  = Temperature rise above the ambient level.

Anatomy of the eyeball describes the normal position of the anterior chamber as a normal eye without glaucoma including the lens, iris and the angle between the iris and the cornea will be  $30^\circ$  in the normal eye seen in Figure 1.

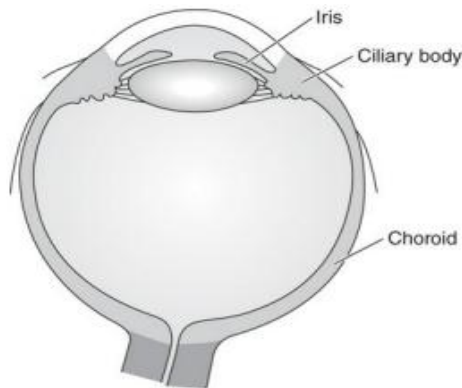


Figure 1: Anatomy of the eyeball [4].

Anatomy of the eye's anterior chamber indicate the aqueous humor secretes from the ciliary body behind the iris and flowout through trabecula miswak and canal of Schemm as seen in Figure 2.



Figure 2: Eye's anterior chamber anatomy.

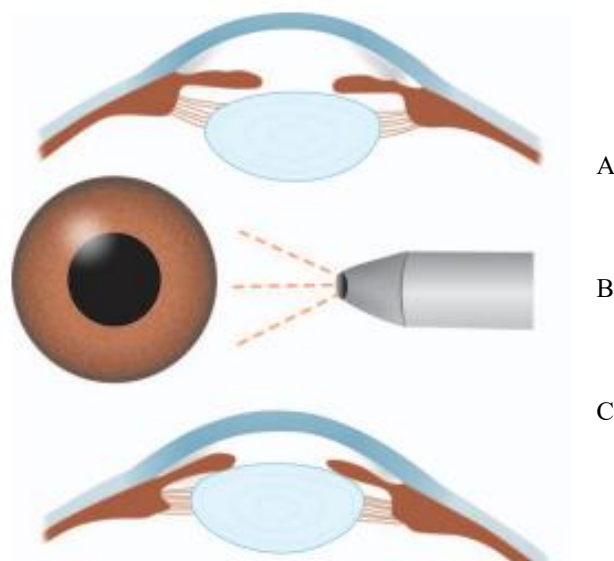


Figure 3 : ABC Eye' anterior chamber ( effected with glaucom, during laser treatment and after laser traitement as in normal eye) [5].

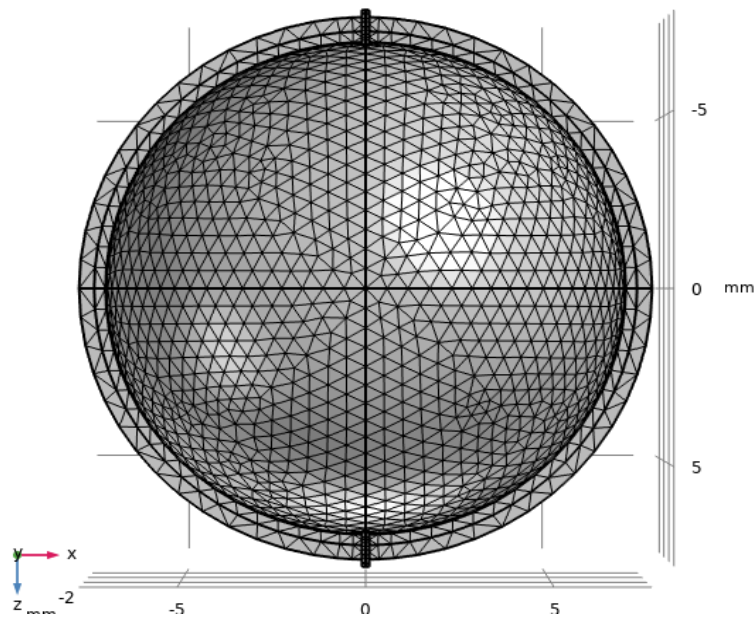


Figure4: A 3D eye anterior chambre model was meshed in COMSOL include posterior cornea surface, trabecula miswak and canal of Schemm.

### III. Method

This study was simulated in the COMSOL Multiphysics environment. A 3D model of the eye's anterior chamber was modeled and meshed to include the posterior surface of the cornea, trabecular meshwork, and canal of Schlemm. The two LASERs, 532nm SLT and 514nm ALT, were simulated in a COMSOL environment with a pulse duration of 2 ms and heat flux of 1000 W/m<sup>2</sup>. The two LASERs were exposed on the eyeball through the canal of Schlemm and trabecular meshwork, as seen in Figure 4. The thermal responses by the eye tissue were measured.

### IV. Results and Discussion

The thermal responses of the eye due to the absorption of the electromagnetic energy carried by the two lasers were measured. The overall thermal responses of the Schlemm's canal were measured and are presented below.

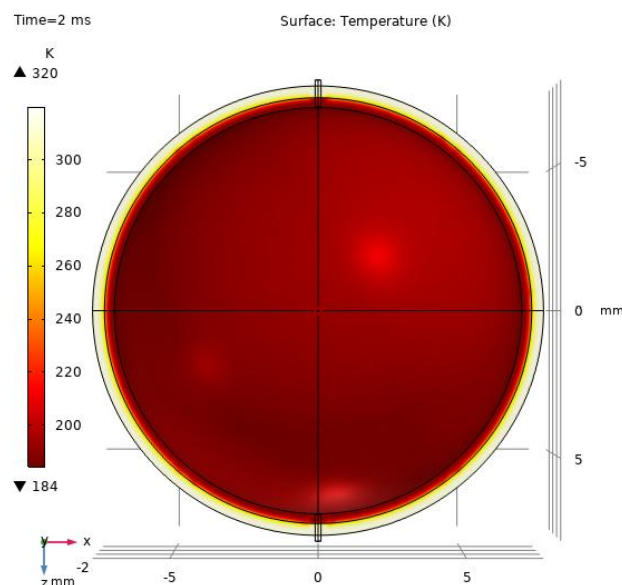


Figure 5: A 3D eye anterior chamber model when exposed to 532nm SLT with a pulse duration of 2 ms and a heat flux of 1000 W/m<sup>2</sup>.

In Figure 5, the result of thermal responses of 310K was indicated on the graphic by the bright yellow color at the outermost part of the eye chamber. When the anterior chamber is exposed to 532nm SLT with a pulse duration of 2 ms and a heat flux of 1000 W/m<sup>2</sup> through the canal of Schlemm and trabecular meshwork, the absorbed heat facilitates the aqueous humor outflow from the eye's anterior chamber due to the resultant expansion of the wall of the chamber.

For the second LASER, we obtained its result as shown in Figure 6.

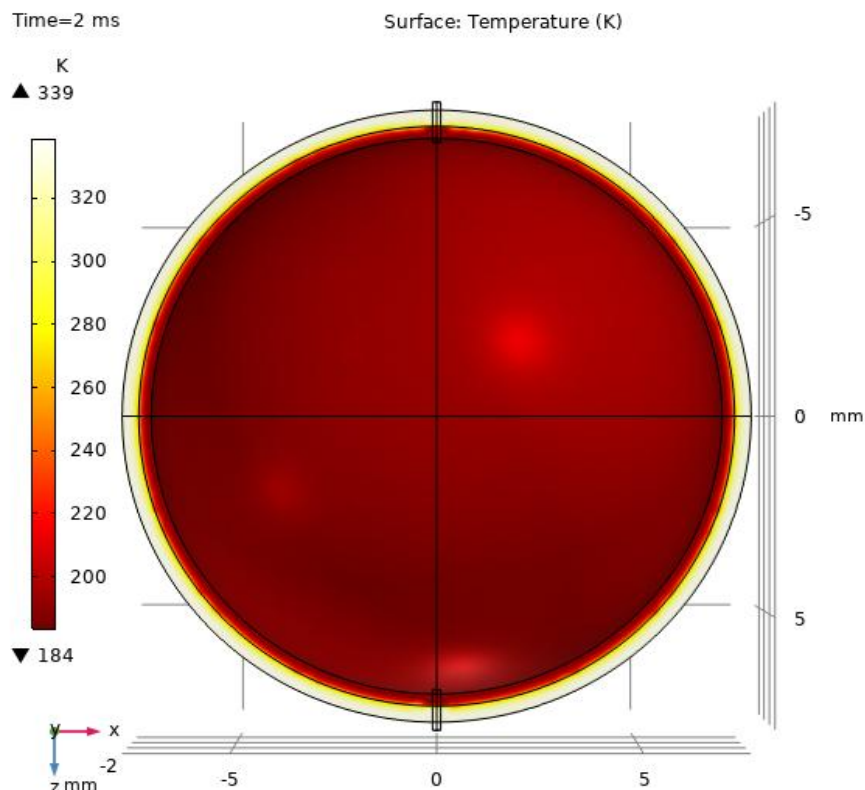


Figure 6: A 3D eye's anterior chambre model of 514nm ALT with plus duration of 2ms and heat flux of 1000W/m<sup>2</sup>.

In Figure 6 the result of thermal responses of 330K was indicated on the graphic by the bright yellow color. When the anterior chambre exposed to 514nm ALT with a pulse duration of 2ms and heat flux of 1000 W/m<sup>2</sup> through canal of Schelm and trabecular meshwork to assist the aqueous humor outflow.

In this study, the finding of 310K thermal responses absorbed by the eye tissue was more effective at reducing IOP and safety for trabecular meshwork tissue damage because of its lower thermal intensity than 330K. Study demonstrated that eyes treated with MLT and SLT had similar treatment success at 1 year, though there was a trend toward greater success with SLT [6]. Pattern scanning laser trabeculoplasty (PSLT) was not superior to SLT in terms of safety and IOP-lowering efficacy in patients with primary open-angle glaucoma (POAG) or ocular hypertension (OHT) [7]. Furthermore, survival analysis demonstrated that the duration of IOP management without the need for the use of IOP-lowering eye drops was similar in bimatoprost implant-treated and SLT-treated eyes. SLT demonstrated a more favorable safety profile compared with the 15-μg bimatoprost implant [8]. SLT is effective in lowering IOP in OAG patients, demonstrating significant efficacy compared to medication and different SLT protocols. The findings underscore SLT's potential as a reliable treatment option [9]. SLT proves effective as both a primary and additional therapy for open-angle glaucoma, significantly reducing medicine usage. The IOP reduction remains consistent in both primary and adjunctive treatment groups during a year of follow-up [10].

## 5. Conclusion

This study evaluated the thermal responses of 532nm SLT and 514 nm ALT on the anterior chamber of the eye through the canal of Schlemm for open-angle glaucoma therapy. The investigation took place in the COMSOL Multiphysics environment. The results demonstrated that a lower thermal intensity of 310K from 532nm SLT with a pulse duration of 2 ms and a heat flux of 1000 W/m<sup>2</sup> was more effective and safer for reducing intraocular pressure (IOP) with minimal risk of trabecular meshwork damage compared to the higher thermal

response of 330K induced by 514nm ALT with the same pulse duration and a heat flux. Finding improves clinical practice in the ophthalmology field.

### References

- [1]. J. S. Yoon, Y. eun Kim, E. J. Lee, H. Kim, and T. W. Kim, "Systemic factors associated with 10-year glaucoma progression in South Korean population: a single center study based on electronic medical records," *Sci. Rep.*, vol. 13, no. 1, pp. 1–10, 2023, doi: 10.1038/s41598-023-27858-z.
- [2]. S. Farooq and A. Rizwan, "Glaucoma Detection and Classification Using Improved U-Net Deep Learning Model," 2022.
- [3]. M. P. Lehekar, "International Journal of Trend in Scientific Research and Development ( IJTSRD ) Implemetation of Kanban," no. June 2021, pp. 598–621, 2017.
- [4]. Vaughan & Asbury's, *General Ophthalmology*, 19th ed. New York Chicago San francisco Athens London: McGraw-Hill Education, Inc, 2018.
- [5]. A. Khurana, *Comprehensive Ophthalmology-Diseases of the Retina 6th Edition*. 2015.
- [6]. C. Q. Sun, T. A. Chen, M. S. Deiner, and Y. Ou, "Clinical outcomes of micropulse laser trabeculoplasty compared to selective laser trabeculoplasty at one year in open-angle glaucoma," *Clin. Ophthalmol.*, vol. 15, pp. 243–251, 2021, doi: 10.2147/OPTH.S285136.
- [7]. M. O. M. Wong *et al.*, "Efficacy and safety of selective laser trabeculoplasty and pattern scanning laser trabeculoplasty: A randomised clinical trial," *Br. J. Ophthalmol.*, vol. 105, no. 4, pp. 514–520, 2021, doi: 10.1136/bjophthalmol-2020-316178.
- [8]. W. C. Christie, M. M. Basha, Q. Ho, K. Kim, E. R. Craven, and M. Kolko, "Phase 3, Randomized Study Comparing Intracameral Bimatoprost Implant 15 µg and Selective Laser Trabeculectomy in Patients with Open-Angle Glaucoma or Ocular Hypertension," *Clin. Ophthalmol.*, vol. 17, pp. 3023–3036, 2023, doi: 10.2147/OPTH.S427976.
- [9]. B. Safarpour Lima and S. Sayanjali, "Effectiveness of laser therapy among patients with open-angle glaucoma: a systematic review and meta-analysis study.," *Eur. J. Transl. Myol.*, vol. 34, no. 4, 2024, doi: 10.4081/ejtm.2024.12931.
- [10]. M. K. Karn, M. Sinha, S. Resident, M. K. Karn, and S. Resident, "Page | 1," vol. 5, no. 3, pp. 1–7, 2024.