

## The Socket-Shield Technique and Immediate Implant Placement- A Clinical Study

Dr Nahida Dar<sup>1</sup>; Dr Tajamul Hakim<sup>2</sup>  
<sup>1,2</sup> MDS ORAL AND MAXILLOFACIAL SURGERY

---

### Abstract

Healing of extraction socket leads to the dimensional changes which will affect the placement of the implant and its emergence profile. Atraumatic extraction, socket preservation technique, and immediate implant placement decrease the alveolar bone resorption by maintaining the postextraction socket. Hürzeler et al. introduced socket-shield technique by keeping a buccal fragment of the tooth to prevent the buccal cortical bone from resorption. This study represents a 10 patients with grossly decayed teeth indicated for extraction replaced with an immediate implant. While examining cone-beam computed tomography, thin buccal cortical plate was noticed which may get fracture during extraction. Socket-shield technique was designed for implant placement to protect buccal bone and to get the proper esthetic form. Two millimeters buccal fragment of the tooth was kept attached and the implant was placed in contact with tooth fragment. Three-month follow-up shows proper healing, and healthy peri-implant tissue shows that socket-shield technique with immediate implant placement will be a good alternative to preserve buccal cortical plate and implant placement, especially in the esthetic area. **Key words:** Anterior implant, immediate implant, ridge preservation, socket-shield technique

---

Date of Submission: 01-12-2020

Date of Acceptance: 15-12-2020

---

### I. Introduction

Extraction of tooth changes the dimension of the alveolar ridge, which has a direct effect on future implant prosthesis and its emergence profile, especially in the anterior region.[1] Trauma during extraction and loss of periodontal ligament were the lead cause of alteration; therefore, many techniques were introduced to prevent the resorption of alveolar bone. Atraumatic extraction, socket preservation, grafting, and immediate implant placement prevent alveolar resorption by preventing the collapse of cortical plates and maintaining the dimension. These techniques show the significant result in maintaining the postextraction alveolar bone, but no studies show the complete preservation of alveolar socket.[2] Araújo and Lindhe suggested that following tooth extraction, the blood vessels in periodontium to the thin bone walls are severed, thereby causing facial bone plate resorption.[1] Thus, it can be assumed that retaining a root may alter the occurrence of facial bone resorption. Many studies showed that the retention of the decoronated root, vital or endodontically treated as root submerge technique, can preserve the alveolar bone.[3] Recent studies also proved that the placement of the implant in contact with retained root surface preserved the buccal bone and led to good emergence profile.[2] Hürzeler et al. were the first to demonstrate the socket-shield technique in a study on one beagle dog. Hemisection of mandibular premolar was performed and a buccal fragment of distal root was retained 1-mm coronal to the buccal bone plate. The immediate implant placement was done lingually to the retained root piece with or without contact with root fragment. No complications were seen, and the histologic study shows that the newly formed cementum was seen in the area between the titanium implant and retained root fragment.[2] Modification of original technique was done by many researchers by preserving the palatal bone and proximal bone.[4] The promising result of these study shows socket-shield technique as a feasible alternative treatment option for thin buccal plate region area and periodontally healthy teeth.

### II. Materials And Methods

10 systemically healthy patients presented with a grossly decayed teeth. An attempt to preserve tooth by root canal treatment failed. Clinical examination showed grossly decayed root canal treated the tooth with healthy gingival and periodontal tissue. After initial examination, the patients were advised for IOPA and Cone-beam computed tomography (CBCT) showed the presence of grossly decayed teeth. Mean Distance from the alveolar crest to the nasal floor was 17.03 mm, and distance from the root apex to the nasal floor was 7.36 mm, labio-palatal thickness showed a maximum of 9.07 mm and minimum of 5.54 mm . According to the CBCT findings implants were selected for the placement to get proper primary stability. While examining the CBCT, it shows the presence of thin buccal cortical plate which may get fracture during the extraction, so socket-shield procedure was design to preserve a buccal fragment of the tooth. Before implant placement, a prophylactic

protocol for implant placement by Misch was followed which included antibiotic 500 mg amoxicillin 1 h before surgery and rinsing with 0.12% chlorhexidine.[5] The area to be operated was anesthetized by infiltration block. Teeth were decoronated with a round coarse-grained diamond bur till the crest of the bone and straight diamond bur was used to remove the gutta-percha filling from the root. Sectioning of the root was done in two steps. In the first step, sectioning was done till apical two-third with the help of tapered diamond bur mesiodistally in parallel to the long axis of tooth direction. In the second step, the direction of the bur was changed to an oblique direction toward the buccal surface to detach the buccal fragment from the palatal . The palatal portion was extracted atraumatically with the help of Coupland elevator and remaining buccal fragment was trimmed by leaving only 2 mm as a shield . The osteotomy was started with lance drill to get a proper ditch, and then, the sequence of the pilot drill, 2.8-mm drill, and 3.2-mm drill was used to enlarge the osteotomy site. Direction indicator was used after every drill to confirm the direction of osteotomy to the adjacent tooth. MIS NP 3.3-mm diameter and 13-mm length was placed, the primary stability of 35 Nmc was achieved with hand wrench in each case, and the cover screw was placed . The apicocoronal position of the implant platform was situated 1-mm apical to the buccal marginal gingiva, and the gap around the implant was filled with bone graft. The buccal flap was released till the mucogingival junction to get the buccal advancement of the flap, and horizontal matrix suture was used to get a proper approximation. Postoperative antibiotics were prescribed and instructions were given, and the patients were recalled after 10 days for suture removal. No postoperative complication was noticed and healing was uneventful. The temporary splinted acrylic crown was given, and the permanent restoration was followed after 3 months.

### **III. Discussion**

In this study, socket-shield technique was used in an area where the buccal cortical plate was thin by keeping root fragment attached to the buccal bone and placement of immediate implant maintain the ridge contour. The results were in consistent with the original technique given by Hürzeler et al. [2] No postoperative complication was seen and healing was uneventful. Preservation of root segment to prevent alveolar bone resorption was shown in many studies.[6-9] Salama et al. reported the root submerge technique, by keeping root submerge in the pontic area to preserve dimension of alveolar bone.[3] Histological studies of Hürzeler showed the cementogenesis between the implant surface and the retained root surface and clinically successful osseointegrated implant. It should be noted that the complete preservation of socket was not seen in many case reports, while Sirompas et al. showed a mean crestal bone loss of 0.18 mm and Chen et al. [14] showed a mean buccal bone loss of 0.83 mm; this is in accordance with this case report where 1-mm buccal bone loss was seen.[10] Krumph and Barnet showed a high success rate of immediate implant placement, and it has many advantages over the delayed loading by reducing the time for a final prosthesis:[11] second-stage surgery and extraction socket provide the proper angulation for the direction of the implant and reduce the chance for the angulated abutment. In this case, the primary stability of 35 Ncm was achieved by extending osteotomy 3 mm beyond the extraction socket.[12] Space between the implant surface and the socket wall was filled with the bone graft as the lingual jumping distance was more than 1 mm. According to Botticelli, if the distance between the implant surface and the socket wall is 0.5–1 mm, there is no need for bone graft to fill the space, but if space is more than 1 mm, grafting is indicated.[13]

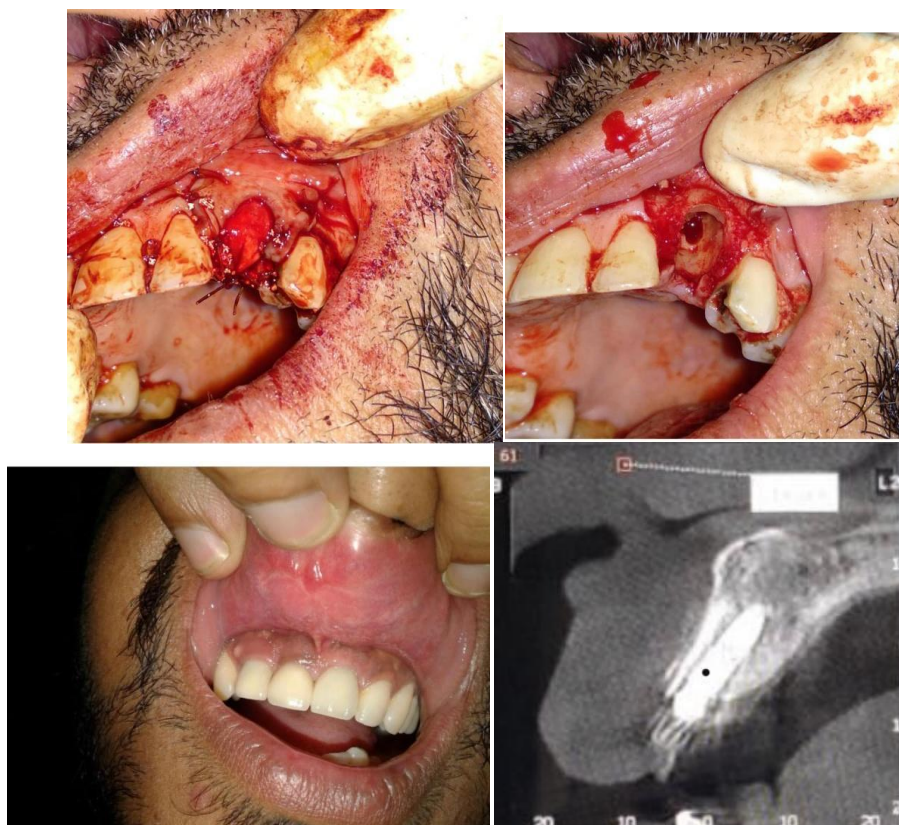
### **IV. Conclusion**

This present study of immediate implant placement with socket-shield technique shows successful preservation of postextraction tissue and thin buccal bone with successful restoration of the implant. Socket-shield technique shows the promising result in the preservation of postextraction socket and holds significant value in implant and esthetic dentistry. Further studies are required to find out the long-term success rate of this technique.

### **References**

- [1]. Amler MH, Johnson PL, Salman I. Histological and histochemical investigation of human alveolar socket healing in undisturbed extraction wounds. *J Am Dent Assoc* 1960;61:32-44.
- [2]. Hürzeler MB, Zuhr O, Schupbach P, Rebele SF, Emmanouilidis N, Fickl S, et al. The socket-shield technique: A proof-of-principle report. *J Clin Periodontol* 2010;37:855-62.
- [3]. SalamaM, Ishikawa T, Salama H, FunatoA, Garber D. Advantages of the root submergence technique for pontic site development in esthetic implant therapy. *Int J Periodontics Restorative Dent* 2007;27:521-7.
- [4]. Kan JY, Rungcharassaeng K. Proximal socket shield for interimplant papilla preservation in the esthetic zone. *Int J Periodontics Restorative Dent* 2013;33:e24-31.
- [5]. Resnik RR, Misch C. Prophylactic antibiotic regimens in oral implantology: Rationale and protocol. *Implant Dent* 2008;17:142-50.
- [6]. Bjorn H. Free transplantation of gingiva propria. *Sven Tandlak Tidskr* 1963;22:684-9.
- [7]. Reames RL, Nickel JS, Patterson SS, Boone M, el-Kafrawy AH. Clinical, radiographic, and histological study of endodontically treated retained roots to preserve alveolar bone. *J Endod* 1975;1:367-73.
- [8]. O'Neal RB, Gound T, Levin MP, del Rio CE. Submergence of roots for alveolar bone preservation. I. Endodontically treated roots. *Oral Surg Oral Med Oral Pathol* 1978;45:803-10.

- [9]. Bowers GM, Chadroff B, Carnevale R, Mellonig J, Corio R, Emerson J, et al. Histologic evaluation of new attachment apparatus formation in humans. Part I. *J Periodontol* 1989;60:664-74.
- [10]. Siormpas KD, Mitsias ME, Kotsiotou-Siormpa E, Garber D, Kotsakis GA. Immediate implant placement in the esthetic zone utilizing the "root-membrane" technique: Clinical results up to 5 years postloading. *Int J Oral Maxillofac Implants* 2014;29:1397-405.
- [11]. Krump JL, Barnett BG. The immediate implant: A treatment alternative. *Int J Oral Maxillofac Implants* 1991;6:19-23.
- [12]. Javed F, Ahmed HB, Crespi R, Romanos GE. Role of primary stability for successful osseointegration of dental implants: Factors of influence and evaluation. *Interv Med Appl Sci* 2013;5:162-7.
- [13]. Botticelli D, Berglundh T, Buser D, Lindhe J. The jumping distance revisited: An experimental study in the dog. *Clin Oral Implants Res* 2003;14:35-42.
- [14]. Chen W-C, Chen C-I. A Preliminary Clinical Study of Buccal Bone Alteration Using the Socket- Shield Technique and Immediate Implant Placement. *J Taiwan Acad Periodontol* 2016;21:137-145. [Downloaded free from <http://www.jisponline.com> on Tuesday, October 2, 2018, IP: 213.234.237.142]



Dr Nahida Dar, et. al. "The Socket Shield Technique and Immediate Implant Placement- A Clinical Study." *IOSR Journal of Applied Chemistry (IOSR-JAC)*, 13(12), (2020): pp 23-25.